

## CASE REPORT

Iran J Allergy Asthma Immunol

December 2023; 22(6):600-603.

DOI: 10.18502/ijaa.v22i6.14648

# Macrophage Activation Syndrome as a Complication of Chronic Granulomatous Disease: A Case Report

Eduardo Liquidano-Perez<sup>1</sup>, Mariana Carmona Berrón<sup>1</sup>, Rosa Itzel Carrillo Nieto<sup>1</sup>, Celso Tomás Corcuera Delgado<sup>2</sup>,  
Lizbeth Blancas Galicia<sup>3</sup>, and Selma Cecilia Scheffler Mendoza<sup>1</sup>

<sup>1</sup> Immunology Service, National Institute of Pediatrics, Secretariat of Health Mexico, Mexico City, Mexico

<sup>2</sup> Pathology Department, National Institute of Pediatrics, Secretariat of Health Mexico, Mexico City, Mexico

<sup>3</sup> Immunodeficiencies Unit, National Institute of Pediatrics, Secretariat of Health Mexico, Mexico City, Mexico

Received: 8 March 2023; Received in revised form: 20 July 2023; Accepted: 26 July 2023

## ABSTRACT

Chronic granulomatous disease (CGD) presents with granuloma formation and lethal infections. It is inherited in an autosomal or X-linked recessive pattern. We describe a 10-month-old patient with a fatal secondary HLH as a CGD primary manifestation. We carried out an autopsy and found noncaseating granulomas, an aspergilloma in the lung, and hemophagocytosis. We performed a DHR assay on the patient's mother and grandmother, showing a bimodal pattern conclusive of X-linked CGD. Thus, our definitive diagnosis was CGD complicated by macrophage activation syndrome. CGD is caused by phagocytes' inability to control pathogens, resulting in granulomas. Secondary HLH is a severe complication and could be characterized by the proliferation of macrophages and T lymphocytes and the production of proinflammatory cytokines. The early suspicion of this presentation helps establish a specific treatment, and the study of the carriers helps determine the etiology.

**Keywords:** Chronic granulomatous disease; Dihydrorhodamine 123; Immunologic deficiency syndromes; Macrophage activation syndrome

## INTRODUCTION

Chronic granulomatous disease (CGD) is an innate immune system disorder inherited in an autosomal or X-linked recessive pattern.<sup>1</sup> In Mexico, there is a lack of epidemiological data on CGD, but the Primary Immunodeficiencies Unit at the National Institute of Pediatrics has studied and reported the characteristics of 93 patients.<sup>2</sup> In the United States, the frequency of CGD is estimated to be 1 in 200,000 new births.<sup>3</sup>

Patients with CGD commonly exhibit diffuse granulomas, failure to thrive, abnormal scarring, hepatosplenomegaly, lymphadenitis, and severe infections. Additionally, they can experience serious complications, such as secondary hemophagocytic lymphohistiocytosis (HLH).<sup>4</sup> In this case presentation, we describe a patient with a severe early presentation of macrophage activation syndrome (MAS) and a history of recurrent infections leading to a lethal outcome.

## CASE PRESENTATION

A 10-month-old boy presented with a 3-month illness characterized by delayed healing of Calmette-

---

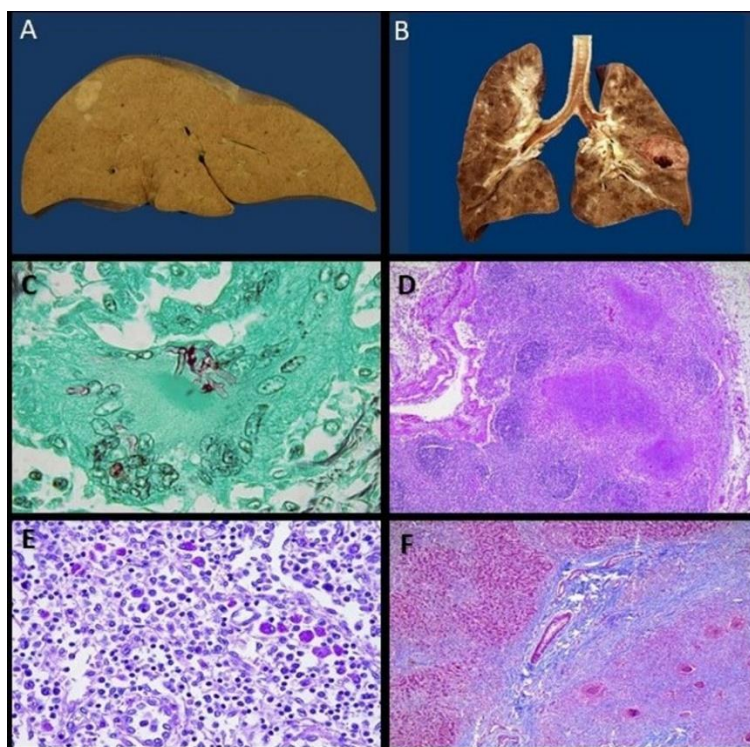
**Corresponding Author:** Selma Cecilia Scheffler Mendoza, MD; Immunology Service, National Institute of Pediatrics, Secretariat of Health Mexico, Mexico City, Mexico. Tel: (+22 55) 1084 0900, E-mail: selmascheffler@gmail.com

## Chronic Granulomatous Disease

Guérin bacillus (BCG) vaccination sites, 7 upper airway infections, 2 cases of gastroenteritis, and intermittent fever. Ten days before admission, he developed a night fever and bloody mucoid stools with a positive test for amoeba infection. Treatment with metronidazole was initiated, but there was no improvement, and respiratory symptoms developed. Physical examination revealed right basal hypoventilation, hepatosplenomegaly, and inflammation at the BCG vaccination site. The complete blood count showed a hemoglobin of 10.6 g/dL, hematocrit of 31.9%, leukocyte count of 23,800/mm<sup>3</sup>, neutrophil count of 20,500/mm<sup>3</sup>, lymphocyte count of 2,600/mm<sup>3</sup>, monocyte count of 700/mm<sup>3</sup>, and platelet count of 346,000/mm<sup>3</sup>. Other test results included a C-reactive protein of 15.6 mg/dl, alkaline phosphatase of 144 UI/L, lactic dehydrogenase (DHL) of 2201 IU/L, aspartate aminotransferase (AST) of 755 IU/L, alanine

aminotransferase (ALT) of 189 IU/L, gamma-glutamyl transpeptidase (GGT) of 129 IU/L, and ferritin of 28,346 ng/mL. The family history revealed that the mother and maternal grandmother had recurrent pregnancy losses, and the patient's brother died at 2 years of age with a history of 10 episodes of gastroenteritis.

The patient's condition worsened despite treatment. Initially, he received penicillin G for pneumonia without improvement, and 24 hours later, ceftriaxone was started. However, 48 hours later, he developed systemic inflammatory syndrome and multiple organ failure. The patient died despite all medical efforts. The autopsy revealed granulomas in the lymph nodes, liver, and lungs, along with an aspergilloma in the middle lobe of the right lung. Hemophagocytosis was observed in the adrenal glands, lymph nodes, thymus, liver, and bone marrow (Figure 1).



**Figure 1.** A) Macroscopic image of the liver section, showing the presence of whitish, lobulated nodules located in the right hepatic lobe. B) Macroscopic image of the lungs section, showing heterogeneous lung parenchyma with congestive and consolidated areas and others preserved. A well-defined nodule with central necrosis is identified at the upper left lung lobe in its lower portion, which corresponds to an Aspergilloma on the microscopic study. C) Microscopic image showing a foreign body type multinucleated giant cell phagocytosing aspergillus (histological section stained with Grocott, 40x). D) Microscopic image of the lymph node showing its altered architecture due to the presence of granulomas with central necrosis (histological section stained with H&E, 5x). E) The Microscope image of the lymph node shows evident hemophagocytes (histological section stained with H&E, 10x). F) Microscopic image of the liver in the transition zone of the preserved parenchyma (upper right) and a zone of necrosis with non-caseating granulomas (zone corresponding to the macroscopic image nodule of the liver); (histological section stained with Masson, 5x)

Due to the rapid and fatal progression, immunological studies could not be conducted on the patient. However, a dihydrorhodamine reduction (DHR) test was performed on the mother and grandmother, both showing bimodal patterns. Additionally, the mother's neutrophils and monocytes were evaluated for the expression of gp91phox, which also exhibited a bimodal pattern. A genetic panel was performed on the carriers, revealing the pathogenic variant c.142-1G>A in the CYBB gene in the mother and grandmother.

## DISCUSSION

Patients with CGD have an impaired ability to form reactive oxygen species (ROS) due to nicotinamide-adenine dinucleotide phosphate (NADPH) defects, resulting in phagocytes being unable to destroy the microorganisms they engulf, leading to persistent and exaggerated inflammation.<sup>1</sup> Salmonella and BCG are the most frequently isolated microorganisms in Latin America in severe CGD infections.<sup>1,4,5</sup> However, in this case, the patient presented with severe infections caused by *Aspergillus*, *Burkholderia*, and secondary HLH, ultimately leading to a lethal outcome. In countries where BCG vaccination is still administered, the initial clinical manifestation of CGD is often adenitis at the BCG vaccination site, as observed in this case.<sup>6</sup>

Secondary HLH is a severe proinflammatory state characterized by fever, hepatosplenomegaly, lymphadenopathy, and coagulopathy, with cytopenias appearing as late findings. Most patients with secondary HLH present with neutrophilia, thrombocytosis, and decreased natural killer cell function.<sup>7</sup> The inability to produce ROS results in the overproduction of proinflammatory cytokines such as interleukin-2, tumor necrosis factor-alpha, and interferon-gamma. These cytokines stimulate macrophages, which secrete high levels of IL-1, IL-6, IL-18, and TNF-alpha, perpetuating a vicious cycle of macrophage overactivation.<sup>8,9</sup> Around twenty cases of secondary HLH associated with CGD have been reported in children. While most of the cases were related to microbial infections, some were associated with inflammatory manifestations.<sup>10</sup>

Given the absence of validated diagnostic criteria, the recognition of secondary HLH is often delayed, as in this unfortunate case. However, a DHR assay was performed on the carriers, confirming the initial diagnostic suspicion. One advantage of this test is its

ability to differentiate between subpopulations of oxidase-positive and oxidase-negative phagocytes in carriers. The degree of residual superoxide production measured by DHR tests provides important prognostic information that correlates with genetic information. The initial DHR test on the mother and grandmother identified an X-linked inheritance pattern, and the family received genetic counseling. It is essential not only to diagnose CGD but also to determine its inheritance pattern and provide guidance to carriers, as they have an increased risk of autoimmune diseases.<sup>3</sup>

CGD remains a poorly recognized disease, and it should be suspected in patients with recurrent infections, complications from BCG, and secondary HLH. Such cases require early and aggressive treatment to eliminate the triggering infectious agent and control the proinflammatory state. Additional studies on the mother and other relatives on the maternal side are recommended for diagnosis and genetic counseling. Traditional and genetic autopsies are valuable diagnostic tools in cases with fatal outcomes.

## STATEMENT OF ETHICS

All procedures were carried out with the prior informed consent of the legal guardian and were authorized by the local ethics committee (No. 019/2011).

## FUNDING

The work presented in this case report did not receive any funding.

## CONFLICT OF INTEREST

The authors declare no conflicts of interest.

## ACKNOWLEDGEMENTS

None.

## REFERENCES

1. Winkelstein JA, Marino MC, Johnston RB, Boyle J, Curnutte J, Gallin JI, et al. Chronic Granulomatous Disease: Report on a National Registry of 368 Patients. *Medicine*. 2000;79(3):155–69.

## Chronic Granulomatous Disease

2. Blancas-Galicia L, Santos-Chávez E, Deswarte C, Mignac Q, Medina-Vera I, León-Lara X, et al. Genetic, Immunological, and Clinical Features of the First Mexican Cohort of Patients with Chronic Granulomatous Disease. *J Clin Immunol*. 2020;40(3):475–93.
3. Ramírez-Vargas GN, Berrón-Ruiz LR, Berrón-Pérez R, Blancas-Galicia L. Diagnóstico de enfermedad granulomatosa crónica; pacientes y portadoras. *Rev Alergia Mex*. 2011;58(2):120-125.
4. Ramírez-Uribe N, Hernández-Martínez C, López-Hernández G, Pérez-García M, Ramírez-Sánchez E, Espinosa-Padilla SE, et al. Trasplante de progenitores hematopoyéticos en un paciente con enfermedad granulomatosa crónica en México. *Rev Alerg Mex*. 2016;63(1):95-103.
5. Bortoletto P, Lyman K, Camacho A, Fricchione M, Khanolkar A, Katz BZ. Chronic Granulomatous Disease. *Pediatr Infect Dis J*. 2015;34(10):1110–4.
6. Salvator H, Mahlaoui N, Catherinot E, Rivaud E, Pilmis B, Borie R, et al. Pulmonary manifestations in adult patients with chronic granulomatous disease. *Europ Resp J*. 2015;45(6):1613–23.
7. Akagi K, Kawai T, Watanabe N, Yokoyama M, Arai K, Harayama S, et al. A Case of Macrophage Activation Syndrome Developing in a Patient With Chronic Granulomatous Disease-associated Colitis. *J Pediatr Hematology/Oncology*. 2014;36(3):e169–72.
8. Van Montfrans JM, Rudd E, van de Corput L, Henter J-I, Nikkels P, Wulffraat N, et al. Fatal hemophagocytic lymphohistiocytosis in X-linked chronic granulomatous disease associated with a perforin gene variant. *Pediatr Blood Cancer*. 2009;52(4):527–9.
9. Kohn DB, Booth C, Kang EM, Pai S-Y, Shaw KL, Santilli G, et al. Lentiviral gene therapy for X-linked chronic granulomatous disease. *Nature Medicine*. 2020;26(2):200–6.
10. Bode SF, Ammann S, Al-Herz W, Bataneant M, Dvorak CC, Gehring S, et al. The syndrome of hemophagocytic lymphohistiocytosis in primary immunodeficiencies: implications for differential diagnosis and pathogenesis. *Haematologica*. 2015;100(7):978–88.