

## CASE REPORT

Iran J Allergy Asthma Immunol

April 2022; 21(2):215-218.

Doi: 10.18502/ijaai.v21i2.9229

# Korean Adolescent Patient with Manifestations of Lymphocyte Variant Hypereosinophilic Syndrome and Episodic Angioedema with Eosinophilia, Treated with Reslizumab

Jie Hee Jue<sup>1</sup>, Ye Jee Shim<sup>1</sup>, Sunggyun Park<sup>2</sup>, Do-Hoon Kim<sup>2</sup>, and Hye Ra Jung<sup>3</sup>

<sup>1</sup> Department of Pediatrics, Keimyung University School of Medicine, Keimyung University Dongsan Hospital, Daegu, Korea

<sup>2</sup> Department of Laboratory Medicine, Keimyung University School of Medicine, Keimyung University Dongsan Hospital, Daegu, Korea

<sup>3</sup> Department of Pathology, Keimyung University School of Medicine, Keimyung University Dongsan Hospital, Daegu, Korea

Received: 29 April 2021; Received in revised form: 15 September 2021; Accepted: 23 September 2021

## Abstract

A four-year-old female patient visited the pediatric hematologic clinic due to periodic generalized edema and eosinophilia. Laboratory assessment showed an eosinophil count of  $40.02 \times 10^9/L$  (73.6% of white blood cells). A bone marrow aspirate smear film showed no signs of malignant cells but had hypercellular marrow particles with eosinophilia (45% of all nucleated cells) and 52% of eosinophils were immature. Other laboratory tests showed an increased IgM level of 827 mg/dL, and lymphocyte phenotyping by flow cytometry revealed an aberrant CD3<sup>-</sup>CD4<sup>+</sup> T-cell population of  $27-53 \times 10^9/L$  (1.9–3.6% of lymphocytes). Polymerase chain reaction analysis for the T-cell receptor gamma gene rearrangement showed a T-cell clonality peak. At the age of 13, allogeneic stem cell transplantation was performed, but with primary rejection. From the age of 17, she has continued receiving 3 mg/kg of reslizumab intravenously every 4 weeks for 21 months. Since reslizumab treatment was initiated, her eosinophil count remained consistently within the normal range. This is the first report describing the effective use of reslizumab in a Korean adolescent patient for the management of lymphocytic-variant hypereosinophilic syndrome (L-HES). Since the patient showed clinical manifestations of L-HES as well as episodic angioedema with eosinophilia (EAE), a continuous periodic examination is required given the higher risk of developing lymphoma or leukemia.

**Keywords:** Angioedema; Eosinophilia; Hypereosinophilic syndrome; Interleukin-5; Monoclonal antibodies; Reslizumab

---

**Corresponding Author:** Ye Jee Shim, MD, PhD;  
Department of Pediatrics, Keimyung University School of Medicine,  
1095 Dalgubeol-daero, Dalseo-gu, Daegu 42601, Korea.  
Tel: (+82 53) 258 7824, Fax: (+82 53) 258 4875,  
E-mail: yejeeshim@dsmc.or.kr

## INTRODUCTION

Hypereosinophilic syndrome (HES) comprises several rare heterogeneous disorders characterized by

peripheral blood eosinophil levels of more than  $1.5 \times 10^9/L$  and associated end-organ manifestations.<sup>1,2</sup> Corticosteroids are the first-line therapy for several HES forms; however, treatment responses are variable and long-term corticosteroid use can lead to several complications.<sup>3</sup> Thus, alternative therapies for corticosteroid-dependent or corticosteroid-refractory HES, including hydroxyurea, interferon- $\alpha$ , imatinib, stem cell transplantation, or anti-interleukin (IL)-5 monoclonal antibodies, have been proposed.<sup>1,2</sup> IL-5 is essential for the differentiation, activation, and survival of eosinophils.<sup>4</sup> Thus, anti-IL-5 antibodies (mepolizumab or reslizumab) have been used for the treatment of various eosinophilic disorders,<sup>4-6</sup> of which reslizumab was also applied to treat several types of HES.<sup>7,8</sup>

Angioedema with eosinophilia (AE) is an allergic disorder characterized by recurrent angioedema, weight gain, and eosinophilia without organ damage,<sup>5</sup> which can be classified as episodic (EAE; Gleich syndrome) and non-episodic AE, with most cases in Koreans being non-episodic.<sup>5</sup> EAE is a very rare and unique subset of lymphocytic-variant HES (L-HES) in which patients have episodic angioedema and urticaria every month with elevated serum IgM and dramatic eosinophilia, but without internal organ invasion, and all manifestations can improve without treatment.<sup>9</sup>

Herein, we describe a female adolescent Korean patient diagnosed with L-HES with typical phenotypes of EAE who was treated with reslizumab. This study was approved by the Institutional Review Board of the Keimyung University Dongsan Hospital (approval No. 2018-02-006-001) and was conducted according to the tenets of the Declaration of Helsinki.

### Case Presentation

A four-year-old female patient was transferred to the pediatric hematologic clinic because of periodic generalized edema, weight gain, skin wheals, and eosinophilia. The patient was treated with oral corticosteroids for 4 months, prescribed at a local clinic. Laboratory assessment showed a white blood cell (WBC) count of  $54.38 \times 10^9/L$ , eosinophil count of  $40.02 \times 10^9/L$  (73.6% of WBC), a hemoglobin level of 104 g/L, and platelet count of  $236 \times 10^9/L$ . Analysis of the peripheral blood smear film showed that the number of leukocytes increased with neutrophilia and demonstrated prominent eosinophilia. No evidence of

secondary or reactive eosinophilia was observed. Bone marrow aspirate smear film showed no signs of malignant cells, but had hypercellular marrow particles, with increased myeloid: erythroid ratio. The number of myeloid series increased with eosinophilia (45% of all nucleated cells), and 52% of eosinophils were immature. Other laboratory tests showed IgG 1,778 mg/dL (reference range: 800–1,700 mg/dL), IgA 274 mg/dL (68–378 mg/dL), IgM 827 mg/dL (60–263 mg/dL), IgE 192 mg/dL (<100 mg/dL), erythrocyte sedimentation rate 42 mm/h (0–25 mm/h), vitamin B12 1,273 pg/mL (197–771 pg/mL), and tryptase 3.4  $\mu\text{g/L}$  (<11.0  $\mu\text{g/L}$ ). Lymphocyte phenotyping using flow cytometry revealed an aberrant CD3<sup>+</sup>CD4<sup>+</sup> T-cell population of  $27\text{--}53 \times 10^9/L$  (1.9–3.6% of lymphocytes). Polymerase chain reaction analysis for the T-cell receptor gamma gene rearrangement showed a T-cell clonality peak of low intensity at 240 and 175 bp. *FIP1L1-PDGFR $\alpha$*  fusion was not detected via fluorescence *in situ* hybridization of a blood sample. Computed tomography of the abdomen and pelvis showed splenomegaly and multiple conglomerated periportal and pelvic lymph nodes, as well as diffuse wall thickening of the urinary bladder and diffuse soft tissue swelling in the lower abdomen and pelvis, which were suspected to be due to eosinophilic infiltration. The patient had distinct features, such as periodic eosinophilia with generalized edema every month and increased IgM consistent with the diagnosis of EAE. However, the observed clinical manifestations including infiltrations of eosinophils to the major organs were much more severe than those reported to date for EAE and were more consistent with the typical characteristics of L-HES. The patient's symptoms did not improve spontaneously; therefore, prolonged corticosteroid administration was required for several years. At age 13, allogeneic stem cell transplantation was performed, but it led to primary rejection.

In 2016, the targeted anti-IL-5 antibody mepolizumab became available in Korea, which the patient started to receive (100 mg of mepolizumab subcutaneously every 4 weeks) at age 15. Thereafter, the eosinophil count decreased below 100–200 cells/ $\mu\text{L}$ , not requiring additional corticosteroid use; however, it gradually increased again despite mepolizumab injection, and the treatment was discontinued. At age 17, treatment with reslizumab, another anti-IL-5 monoclonal antibody, was initiated. To date, for 21 months, the patient has continued receiving 3 mg/kg of

## Lymphocyte Variant Hypereosinophilic Syndromae Treated with Reslizumab

reslizumab intravenously every 4 weeks; resulting in eosinophil counts consistently maintained within the normal range, without report of eosinophilia (Figure 1A). Before reslizumab treatment, the patient's bone age was defined as being 3 years younger than the

patient's chronological age, along with height under the third percentile. Notably, after corticosteroid therapy was stopped and reslizumab treatment was initiated, the patient's short stature improved, with a height reaching the normal range (25th percentile) (Figure 1B).

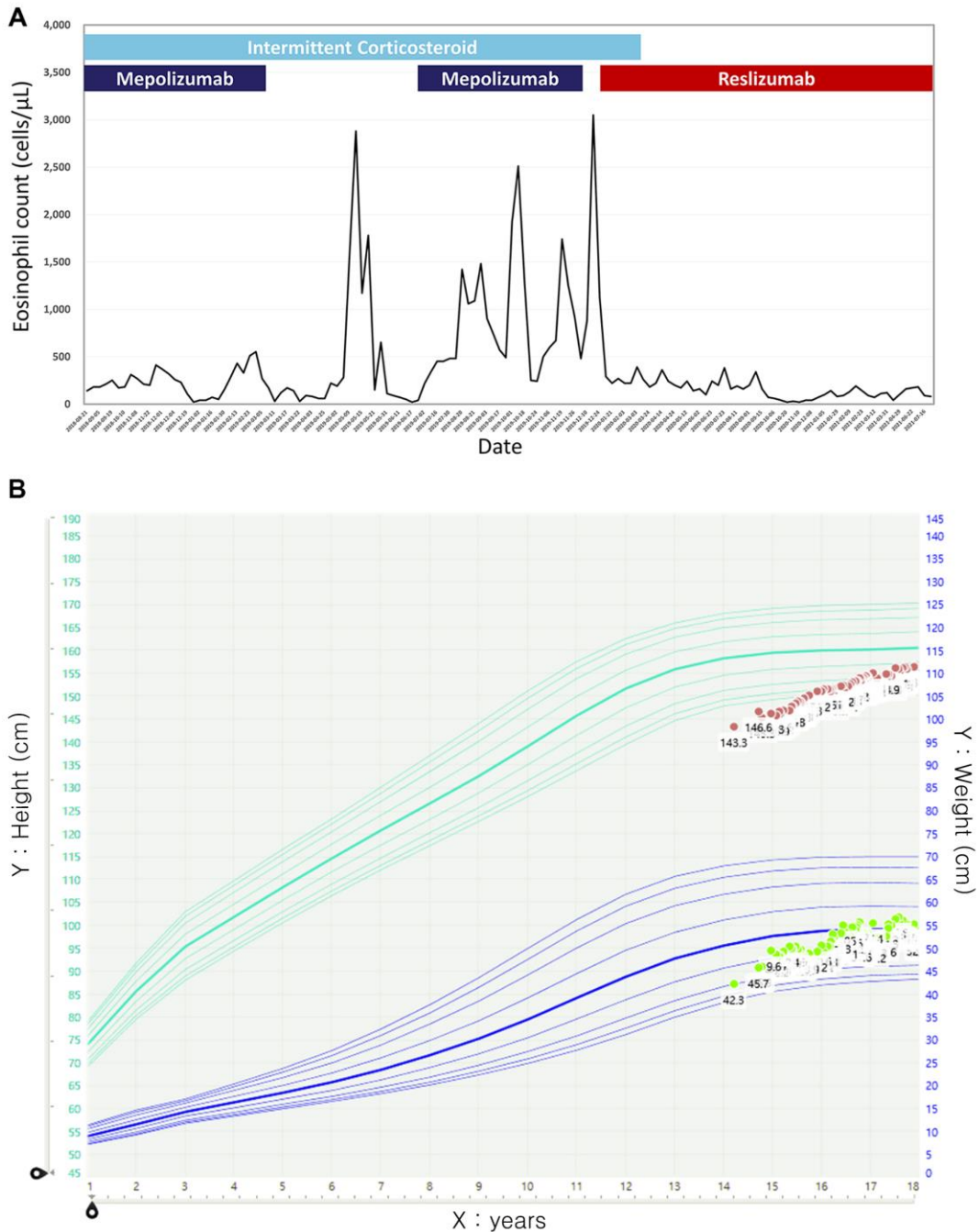


Figure 1. Progress of eosinophil count (A) and percentile of height/weight in growth chart (B) during treatment with reslizumab

## DISCUSSION

The efficacy of anti-IL-5 antibodies for HES was demonstrated by several small-scale clinical trials.<sup>10,11</sup> Although monthly mepolizumab (100 mg) and reslizumab (3 mg/kg) were approved by the U.S. Food and Drug Administration for severe eosinophilic asthma, these dosages are lower than those used in any of the HES trials to date.<sup>12</sup> Thus, we cannot conclude that the mepolizumab treatment was unsuccessful for our patient before attempting a high dose (750 mg).<sup>13</sup> Compared with mepolizumab, reslizumab is much cheaper in Korea (mepolizumab 100 mg=2,007, 218 won vs. reslizumab 100 mg=580, 635 won). Therefore, we decided to apply reslizumab, instead of high-dose mepolizumab.

Herein, we described a very rare and unusual case of a Korean patient who presented characteristics of both typical EAE and L-HES. Notably, this is the first report describing the effective use of reslizumab in a Korean adolescent patient for the management of HES. Moreover, this report provides valuable insights on the progress of a pediatric patient with HES over more than 10 years. Since the patient showed clinical manifestations of L-HES as well as EAE, a continuous periodic examination is required given the higher risk of developing lymphoma or leukemia.

## CONFLICT OF INTEREST

There are no potential conflicts of interest relevant to this article.

## ACKNOWLEDGEMENTS

None.

## REFERENCES

1. Gotlib J. World Health Organization-defined eosinophilic disorders: 2014 update on diagnosis, risk stratification, and management. *Am J Hematol.* 2014;89(3):325-37.
2. Klion AD. How I treat hypereosinophilic syndromes. *Blood.* 2015;126(9):1069-77.
3. Khoury P, Abiodun AO, Holland-Thomas N, Fay MP, Klion AD. Hypereosinophilic Syndrome Subtype Predicts Responsiveness to Glucocorticoids. *J Allergy Clin Immunol Pract.* 2018;6(1):190-5.
4. Legrand F, Klion AD. Biologic therapies targeting eosinophils: current status and future prospects. *J Allergy Clin Immunol Pract.* 2015;3(2):167-74.
5. Chu H, Youn DY, Park HS, Ye YM, Park YB, Ban GY. Non-episodic Angioedema With Eosinophilia Successfully Treated With Reslizumab. *Allergy Asthma Immunol Res.* 2020;12(2):371-4.
6. Walsh GM. Profile of reslizumab in eosinophilic disease and its potential in the treatment of poorly controlled eosinophilic asthma. *Biologics.* 2013;7:7-11.
7. Buttgerit T, Bonnekoh H, Church MK, Bergmann KC, Siebenhaar F, Metz M. Effective treatment of a lymphocytic variant of hypereosinophilic syndrome with reslizumab. *J Dtsch Dermatol Ges.* 2019;17(11):1171-2.
8. Coffey K, Fajt ML, Acho M, Gladwin M, Petrov AA. Successful Treatment of Corticosteroid-Refractory Hypereosinophilia With Reslizumab. *J Investig Allergol Clin Immunol.* 2019;29(3):241-2.
9. Khoury P, Herold J, Alpaugh A, Dinerman E, Holland-Thomas N, Stoddard J, et al. Episodic angioedema with eosinophilia (Gleich syndrome) is a multilineage cell cycling disorder. *Haematologica.* 2015;100(3):300-7.
10. Garrett JK, Jameson SC, Thomson B, Collins MH, Wagoner LE, Freese DK, et al. Anti-interleukin-5 (mepolizumab) therapy for hypereosinophilic syndromes. *J Allergy Clin Immunol.* 2004;113(1):115-9.
11. Klion AD, Law MA, Noel P, Kim YJ, Haverty TP, Nutman TB. Safety and efficacy of the monoclonal anti-interleukin-5 antibody SCH55700 in the treatment of patients with hypereosinophilic syndrome. *Blood.* 2004;103(8):2939-41.
12. Kuang FL, Klion AD. Biologic Agents for the Treatment of Hypereosinophilic Syndromes. *J Allergy Clin Immunol Pract.* 2017;5(6):1502-9.
13. Kuang FL, Fay MP, Ware J, Wetzler L, Holland-Thomas N, Brown T, et al. Long-Term Clinical Outcomes of High-Dose Mepolizumab Treatment for Hypereosinophilic Syndrome. *J Allergy Clin Immunol Pract.* 2018;6(5):1518-27.e5.