

## REVIEW ARTICLE

Iran J Allergy Asthma Immunol

In press.

# Intravenous Immunoglobulin Therapy in Myocarditis

Amir Hossein Mansourabadi<sup>1</sup>, Ladan Gol Mohammad pour Afrakoti<sup>1</sup>,  
Abbas Shahi<sup>1,2</sup>, Reza Shabani<sup>3</sup>, and Aliakbar Amirzargar<sup>1</sup>

<sup>1</sup> Department of Immunology, School of Medicine, Tehran University of Medical Sciences, Tehran, Iran

<sup>2</sup> Students Scientific Research Center, Tehran University of Medical Sciences, Tehran, Iran

<sup>3</sup> Department of Pediatric Cardiology, Children's Medical Center Hospital, Tehran University of Medical Sciences, Tehran, Iran

Received: 14 September 2019; Received in revised form: 30 March 2020; Accepted: 2 April 2020

## ABSTRACT

Myocarditis is an inflammatory disease of the myocardium with lymphocyte infiltration and myocyte necrosis leading to a wide range of clinical presentations including heart failure, arrhythmia, and cardiogenic shock. Infectious and noninfectious agents may trigger the disease. The fact that immunosuppressive drugs are useful in several kinds of autoimmune myocarditis is proof of the autoimmune mechanisms involved in the development of myocarditis. Pathogenic mechanisms in myocardial inflammation are including inflammasome activation followed by myocyte destruction, myocarditis, and pericarditis. Intravenous immunoglobulin (IVIg) is a serum product made up of immunoglobulins, widely used in a variety of diseases. This product is effective in several immune-mediated pathologies. As well as the determined usage of IVIg in Kawasaki disease, IVIg may be useful in several kinds of heart failure including fulminant myocarditis, acute inflammatory cardiomyopathy, Giant Cell Myocarditis, and peripartum cardiomyopathy. Generally, IVIg is used in two different doses of low dose (200 to 400 mg/kg) and high dose (2 g/kg) regimen. The exact therapeutic effects of IVIg are not clear, however over the last decades, our knowledge about its mechanism of function has greatly enhanced. IVIg administration should be based on the accepted protocols of its transfusion. In this review article, we try to provide an overview of the different kinds of myocarditis, pathologic mechanisms and their common treatments and evaluation of the administration of IVIg in these diseases. Furthermore, we will review current protocols using IVIg in each disease individually.

**Keywords:** High dose intravenous immunoglobulin; Inflammation; Intravenous immunoglobulin; Low dose intravenous immunoglobulin; Myocarditis

**Corresponding Authors:** Aliakbar Amirzargar, PhD;  
Department of Immunology, School of Medicine, Tehran University of Medical Sciences, Tehran, Iran. Tel: (+98 21) 8895 3009, Fax: (+98 21) 6642 2337, E-mail: Amiralizar@tums.ac.ir  
Reza Shabani, MD;  
Department of Pediatric Cardiology, Children's Medical Center, Tehran University of Medical Sciences, Tehran, Iran, E-mail: rzshabani@sina.tums.ac.ir

## INTRODUCTION

Heart is an immunological organ that is responding to stress, damage, and even with an antibody response to heat shock proteins.<sup>1</sup> It has been known for years that the heart may be the target of immune system

agents including T lymphocytes, B lymphocytes, and also their products such as cytokines, circulating antibodies, and other mediators.<sup>2</sup> Myocarditis is an inflammatory disease of the myocardium tissue, usually happened following the flu and respiratory or gastrointestinal symptoms,<sup>3</sup> and characterized with cardiogenic shock, severe arrhythmia,<sup>4</sup> heart failure and infiltration of mononuclear cells to the myocardium and myocellular necrosis that can cause to acute cardiac death in both children and adults. Genetic background and epigenetic mechanisms may have a great role in the pathogenesis of the disease.<sup>5,6</sup> Although some types of myocarditis may be idiopathic, but various causes including innate and adaptive immune responses, autoimmune mechanisms, infectious agent include viruses (viral infections are the most important cause), bacteria, protozoa, fungi or toxins, and noninfectious

agents include drugs, may trigger the disease with a broad spectrum of clinical and histological symptoms so, according to Table 1, the causes of disease are incredibly varied. Myocarditis may heal by own or lead to dilated cardiomyopathy (DCM) (1). Despite modern advances, the mortality of acute fulminant myocarditis (AFM) remains high.<sup>7</sup> Myocarditis distinguished by biopsy of cardiac muscle tissue using definite histological, immunohistochemical, and immunological criteria which causes myocellular necrosis.<sup>8</sup> Impaired contraction and dilation of ventricles is the clinical manifestation of DCM, which may have an idiopathic, genetic, viral, or autoimmune reason too.<sup>9</sup> Myocarditis mostly improves over time and spontaneously with no need for special treatment, but some patients develop heart failure and require heart transplantation.<sup>10,11</sup>

**Table 1. Causes of infectious and non-infectious myocarditis**

	<b>Organism</b>	<b>Examples</b>	
infectious	bacteria	Vibrio cholera, Staphylococcus, Pneumococcus, Brucella, Mycobacteria, Streptococci, Legionella, Clostridium, Chlamydia, Haemophilus influenza, Salmonella, Corynebacterium diphtheria, Gonococcus, Meningococcus, Mycoplasma pneumonia	
	fungi	Actinomyces, Aspergillus, Mucormycosis, Blastomyces, Cryptococcus, Nocardia, Candida, Sporothrix schenckii, Histoplasma	
	viruses	DNA viruses	Parvovirus B19, Adenoviruses, Hepatitis B virus, Herpes simplex viruses (HSV) type-1 and 2, Herpesvirus type 6, Cytomegalovirus (CMV), Vaccinia, Varicella-Zoster, Rabies virus, Epstein-Barr virus (EBV)
		RNA viruses	Coxsackieviruses A/B, Rabies virus, Echoviruses, Chikungunya virus, human immunodeficiency viruses (HIV), Influenza, hepatitis C virus (HCV), Measles virus, Respiratory syncytial virus, Rubella, Mumps, Polioviruses
	Protozoa	Plasmodium falciparum, Toxoplasma gondii, Entamoeba histolytica, Leishmania, Trypanosoma cruzi	
	Spirochaete	Treponema pallidum, Borrelia, Leptospira	
non-infectious	Fungi	Candida, Actinomyces, Nocardia, Aspergillus, Cryptococcus, Sporothrix schenckii, Histoplasma, Mucormycoses	
	Parasites and Rickettsia	Rickettsia rickettsia, Echinococcus granulosus, Taenia solium, Schistosoma, Toxocara canis, Trichinella spiralis, Coxiella burnetii	
	Immune and autoimmune	rheumatic fever, smallpox, coeliac disease, ulcerative colitis, Crohn's disease, inflammatory myopathies, Systemic lupus erythematosus (SLE), Rheumatoid arthritis (RA), sarcoidosis, Kawasaki's disease, systemic sclerosis, Juvenile idiopathic arthritis (JIA), Takayasu arteritis, tetanus toxoid vaccinations, and heart transplant rejection	
	Drugs and toxic substances	azithromycin, benzodiazepines, lithium, phenytoin, ampicillin, clozapine, ciprofloxacin, cephalosporins, sulphonamides, penicillin, lidocaine, phenylbutazone, isoniazid, mesalamine, adalimumab, diuretics, thiazide, methyl dopa, metoprolol, colchicine, dobutamine	
	Other causes	Iron, copper, radiation, insect bite, etc...	

## Intravenous Immunoglobulin Therapy in Myocarditis

Compensatory hypertrophy, myocyte loss, fibroid tissue, and immunohistochemical findings along with inflammation of myocardium (myocarditis) seen in 30–40 % of biopsy samples of endomyocardial tissue. Clinical symptoms of myocarditis are heterogeneous, ranging from subclinical disease with normal electrocardiogram (ECG) to abrupt cardiac death and acute heart failure (AHF).<sup>12</sup>

A combination of clinical signs, cardiac imaging, electrocardiogram (ECG) findings, and laboratory testing leads to the exact diagnosis of myocarditis.<sup>13</sup> The definitive diagnosis of disease will be achieved by the elimination of other causes of heart failure. Determination of the real occurrence of myocarditis is difficult because clinical presentations vary from person to person. Criteria for detecting myocarditis in endomyocardial biopsy samples are defined as Dallas Classification.<sup>14</sup> The mentioned assortment was proposed by several cardiovascular pathologists to create identical criteria for the detecting myocarditis in stained endomyocardial biopsy (EMB) which have been used for many years; however, they are limited because of their variation of interpretation.<sup>15</sup> These variations may be including differences with another marker of viral infection and immune activation in the heart muscle, lack of prognostic value, and low sensitivity. Surface antigen staining for anti-HLA, anti-CD3, anti-CD20, anti-CD4, and anti-CD28 are updated histological criteria.<sup>16,17</sup> The latest studies have revealed that criteria based on this type of surface antigen staining have better prognostic value than the Dallas criteria.<sup>14</sup>

### Literature Search Strategy

A broad literature review of electronic databases including PubMed and Web of Science was performed on articles published up to February 1st, 2019. Search series were including ("IVIG" [TiAb]) AND ("Myocarditis" [MeSH Terms]) OR ("High dose Intravenous immunoglobulin" [TiAb]) and (("Myocarditis" [Title/Abstract]) OR ("High dose Intravenous immunoglobulin" [TiAb]) OR ("Inflammation" [TiAb]) AND ("Myocarditis" [MeSH Terms])). Furthermore, the reference lists of articles were screened to find more related studies.

### Autoimmune Myocarditis

The vast spectrum of researches has proved myocarditis can be caused by some types of

autoimmune mechanisms and their association with autoimmune diseases has also shown. For instance, myocarditis develops in 3–15% of SLE patients.<sup>18,19</sup> Furthermore, pericardial manifestations such as pericarditis and pericardial effusion is mostly seen in these patients. The fact that immunosuppressive drugs are useful in several kinds of autoimmune myocarditis and the existence of autoantibodies in the blood circulation of patients is a shred of definite proof for the involvement of autoimmune mechanisms in the development of myocarditis.<sup>20,21</sup> According to Rose et al. More than half of patients with autoimmune myocarditis show autoantibodies against myocardium. They proved this finding by using healthy myocardial tissue as a substrate for IF (immunofluorescent) staining.<sup>22</sup> The results of numerous researches have proved that possibly affected relatives of cardiomyopathy patients with positive anti heart autoantibody have a higher expectancy to emerging the disease than those without anti heart autoantibody.<sup>23</sup> In autoimmune myocarditis, several antigens including heart-specific, and non-specific may be involved in the production of the autoantibodies as a target of the immune system. In several studies, emerging of autoantibodies against cardiac myosin (a good example of heart-specific antigen) was associated with heart failure.<sup>24,25</sup> This antigen is one of the most common immune response inducing heart-specific antigens seen in 86% of patients. According to Warraich et al research, IgG3 is one of the most prevalent autoantibodies found in the patient's sera.<sup>26</sup> Other prevalent autoantibodies found in Dilated Cardiomyopathy patients include Anti Mitochondrial Antibodies (AMA), anti muscarinic receptor antibody,  $\beta$ -1 adrenoreceptor autoantibody, anti sarcolemmal Na-K-ATPase antibody, etc.<sup>27</sup> Myocardial muscle-specific autoantibodies are not only restricted to myocarditis patients but are seen in patients with other kinds of heart failures too. Anti-Cardiac Troponin Autoantibodies is other autoantibodies which have been reported in patients with acute coronary syndrome.<sup>28-30</sup>

### Pathogenic Mechanisms in Myocardial Inflammation

Pathogenic mechanisms in myocardial inflammation are including inflammasome activation followed by myocyte destruction, myocarditis, and pericarditis.<sup>31,32</sup> Inflammasomes are a group of the

cytosolic multiprotein oligomer of the innate immune system that detects pathogenic microorganisms and sterile stressors, generally including caspase-1, Inflammasome Adaptor Protein Apoptosis-Associated Speck-Like Protein Containing CARD (ASC), and the NOD-like receptor (NLR) family sensor protein that activates the interleukin-1 $\beta$  (IL-1 $\beta$ ) and interleukin-18 (IL-18) pro-inflammatory cytokines.<sup>33</sup> Myocyte destruction can be a result of a bacterial or viral infection, trauma, and cardiac toxicity or stimulation in the earlier phase of the innate and late phase of the adaptive immune system.<sup>1</sup> Immune complexes can have a role in the pathogenic process of myocarditis because of complement-fixing antibodies that find in the circulating blood and sera of patients.<sup>3</sup> Myocyte necrosis in myocarditis patients can be evaluated by measuring serum Troponin I (TnI) level which significantly correlated with heart failure symptoms<sup>34</sup> and usually elevated earlier than CK-MB in pediatric and adult's acute myocarditis. Measuring erythrocyte sedimentation rate (ESR), and C-reactive protein (CRP) that are nonspecific serum markers for systemic inflammation and also, elevated N-terminal pro-brain natriuretic peptide (NT-pro BNP) for the assessment of heart failure may be helpful.<sup>3</sup> Clinical symptoms are varied, including chronic or acute heart failure, lethal cardiogenic shock, and life-threatening ventricular rhythm disturbances.<sup>1</sup>

### **Intravenous Immunoglobulin**

Intravenous immunoglobulin (IVIG) is a serum product made up of immunoglobulins, gathered from the blood of more than a thousand donors per batch. This kind of infusion therapy has been widely used in a variety of diseases. Previous studies indicated that IVIG had been used for the treatment of autoimmune and inflammatory diseases.<sup>35-37</sup> This product is expensive and limited for accessibility because of producing by plasma from the blood of healthy donors. As kinds of immunoglobulins exist in the IVIG preparation so various kinds of activities may occur, therefore it is serious to know documents presented for the effect of IVIG in different situations but despite all these points, according to transfusion protocols, this kind of infusion therapy is usually safe and applicable.<sup>38</sup>

IVIG is used at two different doses including a low-dose (200 to 400 mg/kg, three times a week) and a high-dose (2 g/kg/monthly).<sup>39-42</sup> The low-dose of IVIG

is used as replacement therapy in primary and secondary immunodeficiency and some other malignancies but the high-dose is used as an immunomodulatory purpose in multiple kinds of immune disorders and inflammatory diseases (Figure 1).<sup>43,44</sup> For the first time, a high dose of IVIG was used for pediatric immune thrombocytopenic purpura (ITP). Vast clinical applications of IVIG is in the fields of immunology, nephrology, neurology, rheumatology, dermatology, hematology and to treat multiple diseases including multifocal motor neuropathy (MMN), Guillain Barre syndrome, chronic inflammatory demyelinating polyneuropathy (CIDP), dermatomyositis, stiff person syndrome, and myasthenia gravis (Table 2).<sup>45-47</sup> The mechanisms of function of IVIG are not clear, but over the last decade, great developments in understanding have occurred. IVIG is efficacious in several components that include variable regions F(ab)<sub>2</sub> that effectuate inhibition of proliferation effects, induce apoptosis, inhibition cell cycle by arrest of the cell cycle between the G<sub>0</sub> and G<sub>1</sub> phase and inhibits entering S-phase, decreases T cells adhesion to the extracellular matrix, and contains natural IgG antibodies, Anti-idiotypes, Antibodies to pathogens, superantigens and immunoregulatory molecules, and reduce levels of cytokines.<sup>48,49</sup>

Another component is Fc region on a range of Fc receptors (FcR), that binding of IVIG to Fc $\gamma$ RIIb effectuate deactivation of phagocytosis, inhibition of ADCC and DC maturation, Saturation of them can enhancing catabolism of endogenous IgG and decreasing levels of autoantibodies in some models.<sup>50</sup>

Complement-Fc binding is another component that modulates complement activity, and the last ones are other molecules that include cytokines, cytokine receptor, CD4, etc.<sup>13</sup> The other mechanisms include changing in circulating cytokines, inhibition of cell-mediated cytotoxicity, alter chemokines levels, anti-viral and anti-microbial properties, down-regulation of metalloproteinase, B and T cell inhibition & regulation and inhibiting the protective action of neonatal FcR.<sup>51-54</sup> Administration of immunoglobulin is vital because of the role of them to the neutralization of the virus and microbial toxin and blocking of Fc receptor,<sup>55</sup> but IVIG may have both short-term or long-term outcomes.<sup>56</sup> Studies have suggested that IVIG induced levels of IL10 anti-inflammatory cytokine, the antagonist of IL1R and soluble TNFR and decreased

## Intravenous Immunoglobulin Therapy in Myocarditis

cardiac inflammatory and proinflammatory cytokine which has negative effects and reduction of oxidative stress that it is adverse inotropic effects result from the production of nitric oxide by pro-inflammatory mediators.<sup>57</sup> Treatment patient with IVIG decreases TNF $\alpha$ , IL-6, and thioredoxin (TRX), a small ubiquitous protein, levels and other pro-inflammatory mediators

that have a toxic role in the pathogenesis and decreases matrix metalloproteinase (MMPs) secretion from mononuclear cells that are a mediator of atherosclerosis.<sup>57</sup> It is essential to consider that multiple mechanisms may engage concurrently and not all the potential mechanisms of function fit completely into the mentioned classifications.

**Table 2. The most applications of IVIG in different fields**

Field of application	Examples of application
immunology	CVID, HIGM, XLA, WAS, CLL, myeloma, drugs
neurology	Dermatomyositis, Multifocal motor neuropathy, Stiff person syndrome, Myasthenia gravis, Guillain Barre syndrome, inflammatory myopathies, Lambert–Eaton syndrome, Chronic inflammatory demyelinating polyneuropathy
hematology	Immune thrombocytopenia, CLL, Myeloma, Immune hemolytic anemia, and Immune neutropenia, Post bone marrow transplant, Severe Aplastic Anemia following Parvovirus B19
dermatology	Toxic epidermal necrolysis, Kawasaki syndrome, Blistering diseases, Dermatomyositis, Atopic dermatitis, Pyoderma gangrenosum, Scleromyxoedema, Immune urticaria
others	SLE, Mucous membrane pemphigoid, Birdshot retinochoroidopathy, Vasculitis, Autoimmune uveitis, Streptococcal toxic shock syndrome

IVIG mainly uses at a dose of 2 g/kg for the symptom listed in rheumatology, neurology, hematology, dermatology, and other diseases while in immunology replacement doses (0.4 g/kg) is given. The mentioned list is not comprehensive but to cover disorders which IVIG is frequently administered. XLA, X-linked agammaglobulinemia; WAS, wiskott Aldrich syndrome; CVID, Common variable immunodeficiency; CLL, chronic lymphocytic leukemia; HIGM, Hyper-IgM syndrome; SLE, systemic lupus erythematosus;

### IVIG in Myocarditis

Acute myocarditis occurs in all age groups and usually beginning by a viral infection. Also, the disease could have happened in autoimmune forms.<sup>58</sup> The current pieces of evidence proved the role of IVIG in patients with acute myocarditis (AMC).<sup>56</sup> Myocyte damage induced by humoral immunity may be prevented by Anti-idiotypic properties of IVIG preparations.<sup>41</sup> Indeed, there is limited data to support the concept of the benefits of IVIG in AMC. Further supportive evidence for a beneficial effect of IVIG in myocarditis comes from a mouse model in which polyclonal immunoglobulin has been demonstrated to protect against myocardial damage. Administration of IVIG myocarditis is not considered as a routine method yet, and more researches are needed to specify which patient will respond to the IVIG replacement therapy.<sup>57</sup> The result of a study has shown that high-dose administration of IVIG for the patient with acute myocarditis is connected with improved left ventricular ejection fraction recovery and with a more remarkable survival rate during the first year following administration of IVIG.<sup>7</sup> Another study indicated that

IVIG was not effective in pediatric myocarditis regardless of the types of treatment.<sup>56</sup> Animal studies have suggested that IVIG treatment in Coxsackievirus B3 reduced cellular infiltration, calcification, and necrosis of myocardium followed by better survival rates.<sup>59</sup> This finding demonstrated that advantageous of IVIG in the treatment of the myocarditis is greater when the treatment is initiated at early stages.<sup>60</sup> Chronic heart failure (CHF) is a disease with high mortality involving ischemic dilated cardiomyopathies which exhibit increase inflammatory cytokines such as IL-6, IL-1 $\beta$ , and also TNF $\alpha$  but by an inadequate elevation of anti-inflammatory cytokines so, various studies have concentrated on the role of anti-TNF $\alpha$  in treating HF patients, but because of the failure of this treatment, they led to more general immunomodulatory approach, that treatment with IVIG was considered.<sup>61</sup> The possible functional mechanisms of IVIG in the cardiomyopathy include (Figure 1): altering the affinity of the FCRs, impair adhesion of leukocyte to endothelial cells, antigen neutralization, functional blocking of Fc $\gamma$ R on phagocyte cells, disrupting the apoptosis process through up-regulating

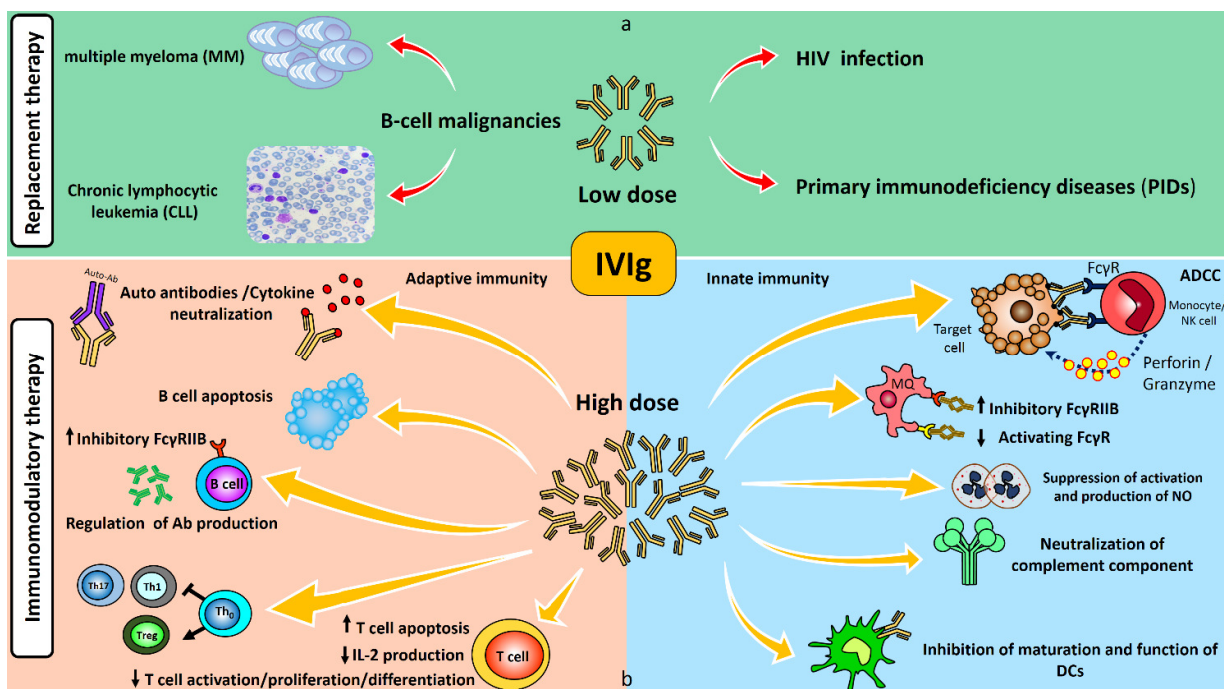


Figure 1. Schematic demonstration of Intravenous immunoglobulin (IVIg) mechanisms of action. a) In this part, mechanisms of low-dose IVIg as a replacement therapy has shown. It can use in primary and secondary immunodeficiency and some other malignancies. b) In this part, mechanisms of high-dose IVIg as an immunomodulatory therapy have shown. High-dose IVIg can exert its immunomodulatory effect on both innate and adaptive immunity.

FLIP (FLICE-inhibitory protein) caspase inhibitor, impairing apoptosis mediated by Fas-L, disrupting DC function because of the role of dendritic cells in the shift from acute infectious myocarditis to chronic autoimmune cardiomyopathy, auto-antibodies neutralization, inhibition of complement activation through binding to C1q, C3, C4, C3b, and inflammatory anaphylatoxin C5a, inhibition of MMP-9 activity in macrophages. Therefore, IVIg may affect cytokine modulation and down-regulation of inflammatory responses.<sup>12</sup>

### IVIg in Kawasaki Disease

Kawasaki disease (KD) is an acute febrile disease with vasculitis of the medium-sized arteries and cardiac complication, rare in adults but common in early childhood.<sup>62</sup> In the early 1980s, the first high-dose IVIg therapy was done for the patient with KD.<sup>63</sup> Furusho et al proposed that IVIg in high-dose in these patients had an anti-inflammatory effect and may prevent coronary aneurysm (CAA) formation.<sup>64</sup> The average age of the disease is about two years old and is

rare in older children. Patients with KD often suffer chronic damage in myocardial tissue, and their coronary arteries are also affected. At the onset of the disease, neutrophils invade the artery walls followed by the gathering of eosinophils, T cells, macrophages, and other inflammatory cells, so these processes beginning with innate immune response. Also, genetic predisposition is involved in KD. KD is a well-known FDA approved indication for IVIg therapy. Various researches have indicated the role of IVIg in KD treatment.<sup>55</sup> IVIg administration in KD leads to a significant decrease in CAA when given within ten days after the onset of fever. Some studies have indicated that treating with IVIg and aspirin at the same time may be effective in KD, so they suggested to administer the second dose of IVIg after administration of the first dose with aspirin, although some of the patients are resistant to treatment with IVIg, so they are in risk of development of coronary artery aneurysms rather than the other patient. The other therapy can be used in patients include corticosteroids, cyclosporine, or cyclophosphamide.<sup>65</sup> About the

## Intravenous Immunoglobulin Therapy in Myocarditis

application of IVIG in KD, there have been almost more than 300 publications containing clinical trials and Cochrane review. The results proved that children who show the symptoms of the KD should be given IVIG at a single dose of 2 g/kg within the first ten days after the beginning of symptoms.<sup>66-68</sup>

### **IVIG in Fulminant Myocarditis**

Fulminant myocarditis (FM) is an uncommon acute form of myocarditis with rapid progression of circulatory failure and high mortality.<sup>69</sup> The main characteristic of FM is a rapidly progressive clinical course with the need for hemodynamic support. According to clinical studies, IVIG treatment in FM patient has shown efficacious. Some studies have indicated that IVIG can improve the left ventricular function (LVF) and decrease the arrhythmia in adult patients. According to a cohort study conducted by DAN-QING YU et al 32 FM patients were treated with IVIG with a dose of 400 mg/kg per day for five days. The results of this study have shown that the FM patients that received Intravenous immunoglobulin had a better left ventricular end-diastolic diameter (LVDD) and left ventricular ejection fraction (LVEF) compared with the control group 4 weeks after the treatment.<sup>70</sup> The atrioventricular block (AVB) and the ratio of ventricular tachycardia/ventricular fibrillation (VT/VF) was reduced after treatment in the patients who received IVIG compared with the baseline values. Despite all these results, no significant difference between patients with IVIG treatment and control groups was observed following treatment. Although IVIG may have improved on LVEF and decrease arrhythmias, there is no valid evidence that has shown IVIG can decrease mortality of FM patients.<sup>71,72</sup>

### **IVIG in Acute Inflammatory Cardiomyopathy**

Acute Inflammatory Cardiomyopathy is determined as a myocardium disease associated with cardiac dysfunction.<sup>73</sup> In recent years, the classification and definition of inflammatory cardiomyopathy have evolved extremely. Acute inflammatory Cardiomyopathy can be classified into primary and secondary categories. The primary category is consisted of genetic, mixed, or acquired form which results in diverse phenotypes such as dilated, hypertrophic, and restrictive patterns.<sup>74</sup> In the development and severity of the disease, the role of T lymphocytes and immune mechanisms has been

proved. Although for myocarditis and dilated cardiomyopathy, the autoimmune mechanism has been assumed, immunosuppressive drugs were not been shown to be effective, but in-vitro studies revealed that IVIG is an effective therapy for viral myocarditis according to their anti-inflammatory and antiviral effects.<sup>75</sup> The vast spectrum of researches has been revealed that the administration of IVIG in these patients, may decrease the level of inflammatory cytokines in blood circulation and consequently, improving the LVEF. Studies have also been reported that administration of IVIG can increase TRX, in patient's sera and reduce oxidative stress.<sup>16</sup> In studies conducted around the use of IVIG in acute inflammatory cardiomyopathy, generally, 1–2 g intravenous IVIG per kg over 2 days have used.

### **IVIG in Giant Cell Myocarditis**

Giant cell myocarditis (GCM) is an uncommon, quickly progressive, and fatal cardiovascular disorder determined by cardiomyocyte necrosis and mixed multinucleated giant cells infiltration in the myocardium.<sup>76</sup> It commonly affects middle-aged and young healthy adults.<sup>77</sup> In a case study around the application of IVIG in a patient with GCM, approximately 500 mg per kg IVIG was administered every three weeks.

### **IVIG in Peripartum Cardiomyopathy**

Peripartum cardiomyopathy (PPCM) is a rare heart failure which generally happened during the last month of pregnancy or up to five months after delivery. According to New York Heart Association system, there is a classification for severity of symptoms in patients with PPCM including, Class I: without any symptoms, Class II: moderate impact on function or symptoms only with extreme exertion, Class III: Symptoms with minimal effort, and Class IV: Symptoms even at rest. Because of the unknown etiology of PPCM, most studies have been focused on hemodynamic of pregnancy and immunologic stresses.<sup>78</sup> The current evidence reported that treatment with immunosuppressive agents could be useful. Also, according to multicenter studies, administration of the high dose of IVIG for women with PPCM with severe dysfunction of left ventricular lead to early recovery of this failure.<sup>79</sup> According to the studies, although patients treated with 2 g/kg (1 g/kg q.d. intravenously on two consecutive days) IVIG had a more

considerable improvement in ejection fraction in comparison with patients treated conventionally, this therapy merits further study.<sup>57,80,81</sup>

### Safety of IVIG Therapy

High-dose administration of IVIG has various adverse effects classified according to their severity including common and mild side effects and rare but serious side effects (Figure 2).

In most patient, complications of IVIG therapy are mild and temporary including fever, face flushing, fatigue, chills malaise, myalgia, headache, nausea, vomiting, diarrhea, dyspnea, back pain, hypertension, and tachycardia that present in the early minutes of IVIG administration that typically resolve within several

days after onset, but in rare cases, severe complications including transfusion-related acute lung injury (TRALI), thromboembolic complications such as deep vein thrombosis (DVT), myocardial infarction (MI), pulmonary emboli, IgA deficiency, lung injury, stroke, cerebrovascular incident and acute renal failure which is the risk factors of renal disease, hypertension, poor hydration, diabetes mellitus, and hyperviscosity are seen.<sup>82,83</sup>

Generally, administration of IVIG is safe when injecting slow and sufficient and it is better to prevent injecting to the patient with high-risk factors.<sup>84</sup> Precise, constant, and exact monitoring by educated staff during the administration may result in the early detection of adverse events.

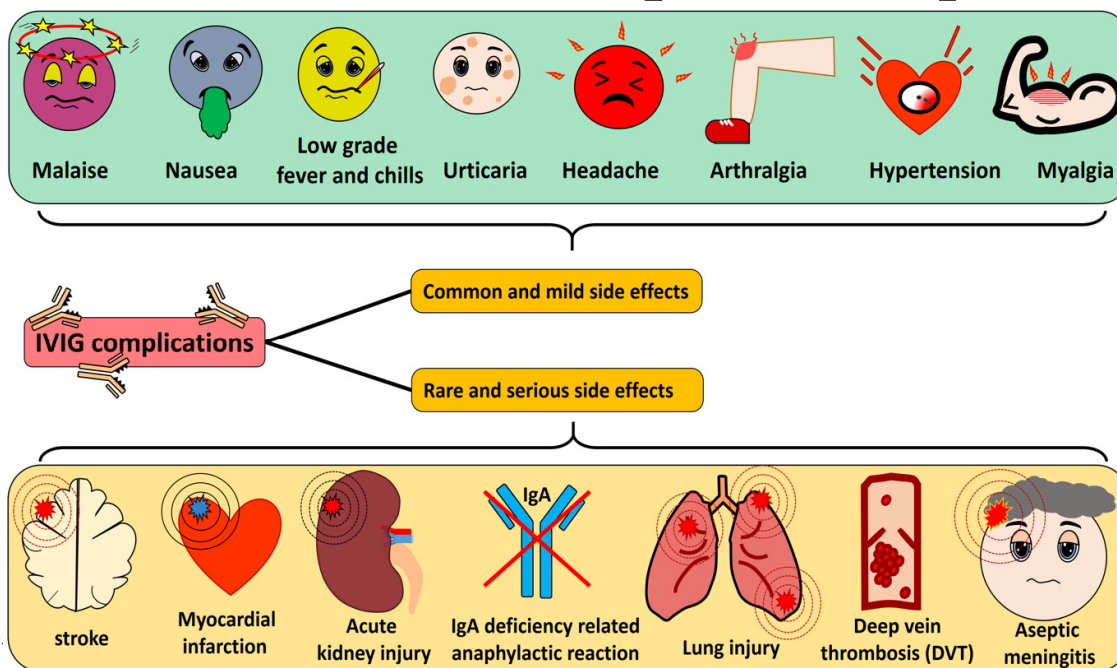


Figure 2. The proposed adverse effect of Intravenous immunoglobulin (IVIG) administration. The vast spectrum of adverse effect include common and mild side effects and rare but serious side effects can be seen.

### DISCUSSION

In experienced hands indicated the acute and chronic myocarditis treatment depends on the severity, causes of the disease, onset of treatment, and also the potential of the myocardium to indemnity for such processes. Drugs can cause inflammation by direct toxic effects on Cardiac muscle and also, caused

hypersensitivity reactions, that are associated with eosinophilic myocarditis that saw in myocarditis.<sup>3</sup> Researches have shown that interferons, Statins, and immunoabsorption have a positive effect on LVEF, Nevertheless, there is low efficiency. Continuously administration of statins despite low costs and few side effects has only a moderate impact on LVEF reduction and has no significant impact on proven non-ischemic



## Intravenous Immunoglobulin Therapy in Myocarditis

cardiomyopathy.<sup>7</sup> based on various studies, the myocardial function may improve by Mesenchymal stem cell (MSCs) therapy. MSCs are non-hematopoietic multipotent stromal cells originally identified in the bone marrow but could be isolated from some other tissue including Adipose tissue, Cord cells, Amniotic fluid, and Molar cells, with non-immunogenic, anti-apoptotic, anti-Fibrotic and immunomodulatory properties through Interferon-gamma by induces nitric oxide (NO) and they can also induce regulatory T cells, suppress T-cell responses and to cause apoptosis of activated T cells.<sup>85,86</sup> Clinical studies also suggested stimulating the direct antiviral immune response, inhibiting viral replication, angiotensin receptor blockade, or ACE-inhibition.<sup>1,3</sup> Non-steroidal anti-inflammatory drugs (NSAIDs) including cyclooxygenase inhibitors such as ibuprofen should be allocation for patients with additional pericardial involvement. Treatment with colchicine, a highly poisonous alkaloid which inhibits the mitosis of tubulin in neutrophils and macrophages that inhibits the innate immune system is another option which suggested for the first attack of pericarditis.<sup>87</sup> Another study demonstrated the beneficial effect of interferon on left ventricular ejection fraction.<sup>88</sup> According to previous studies illustrated, Immunoabsorption and IVIG substitution was related to a greater improvement in LVEF and Immunoabsorption is to reduce cardiotoxic antibodies in the plasma.<sup>86</sup> Based on various case series and case reports studies at many health care centres, IVIG has become part of routine action for treating children and adults with myocarditis.<sup>44,89,90</sup> Researchers have demonstrated remarkable amelioration in left ventricular contractility and function of myocardium after IVIG treatment in myocarditis.<sup>91,92</sup> IVIG indicated advantages in several inflammatory settings, experimentally and clinically. In IVIG therapy, several key points exist: in the first place, IVIG interacts widely with the immune system so immunoglobulin G (ivIgG) and IgGAM Pentaglobin (in lower concentrations than ivIgG), exhibit both anti-inflammatory and proinflammatory effects.<sup>93</sup> According to Anthony et al the anti-inflammatory effects of monomeric IgG is utterly dependent on the N-linked glycan sialylation of Fc fragment of IgG.<sup>94</sup> IvIgGAM can reduce oxidative stress and the IgM fraction in this complex can play a prominent role in controlling some kinds of autoimmune and inflammatory diseases. According to

studies, IgM-enriched immunoglobulins seem to be helpful in lower doses.<sup>93</sup> Based on previously published articles, the first dose of IVIG is administered during different times, but routinely, it administers during the index hospitalization within 24 hours of the right ventricular catheterization and endomyocardial biopsy.<sup>95</sup> In the following, we reviewed some papers that have used different protocols for IVIG therapy.

There are two treatment protocols routinely used in the treatment of myocarditis, including a high dose of IVIG and a low dose of IVIG, depending on the conditions available.<sup>96,97</sup> High-dose of IVIG has an immunomodulatory effect which is advantageous in myocarditis due to Kawasaki disease, as well as in murine models of myocarditis. In patients with idiopathic myocarditis, peripartum cardiomyopathy or dilated cardiomyopathy, high-dose IVIG therapy has been tried and a clinical benefit has been found in some cases.<sup>4</sup> Drucker et al. believe that, since 1990, the routine management of acute myocarditis at Children's Hospitals in Los Angeles and Boston, have included administration of high-dose IVIG.<sup>42</sup> The results of this study suggested that the administration of IVIG in high-dose for curing myocarditis is associated with a tendency to better survival and recovery of LVF during the first year after the myocarditis treatment. In a study by Drucker et al., 2 g/kg single dose of IVIG had been used. The results of this study have revealed that this dose could reduce LVEDD (left ventricular end-diastolic diameter) significantly.<sup>42</sup> In another study performed by McNamara et al with 2 g/kg single dose of IVIG for each patient, improvement of EF (ejection fraction) was seen.<sup>98</sup> In a case series study by Kishimoto et al 1–2 g/kg single dose of IVIG were used for a total of 9 myocarditis patients and improvement of EF was seen too.<sup>99</sup> In another research conducted by Maisch et al the doses of 20 g IVIG per person on days 1 and 3 were used. In this study, out of 126 patients, 90 patients had myocarditis caused by PBV19 (Parvovirus B19), and 36 patients had myocarditis caused by ADV (adenovirus). The results of this study have shown that in 90% of patients, improvement of EF, in 90% of patients, eradication of ADV, in 100% of patients, decreasing of inflammation and in 40% of patients, elimination of PBV19 were seen.<sup>100</sup> In a case report conducted by TEDESCHI et al, the high dose of IVIG which used was 400 mg kg<sup>-1</sup> x day<sup>-1</sup> administered for 5 days. The results have shown quick recovery in the clinical manifestations including

the disappearance of the apical thrombus and the enhancement of LVEF from 30% to 75% during one week after treatment. An electrocardiographic control showed persistent diffuse negative T waves with the normalization of the ST-segment.<sup>101</sup> The result of this review article showed that the time and the dose of IVIG administration for myocarditis patients depends on different factors including the type of myocarditis, patient's age, and severity of the disease, and the same protocol cannot be used for all patients, so, some patients may receive 2 g/kg of IVIG, while the other patients may receive 1 g/kg, 0.5 g/kg, 400 mg/kg or less in different periods.<sup>56,102,103</sup>

### CONFLICT OF INTEREST

The authors declare no conflicts of interest.

### ACKNOWLEDGEMENTS

None declared.

### REFERENCES

1. Maisch B. Cardio-Immunology of Myocarditis. Focus on Immune Mechanisms and Treatment Options. *Front Cardiovasc Med.* 2019;6(48).
2. Maisch B, Trostel-Soeder R, Stechemesser E, Berg P, Kochsiek K. Diagnostic relevance of humoral and cell-mediated immune reactions in patients with acute viral myocarditis. *Clin Exp Immunol.* 1982;48(3):533.
3. Schultheiss H-P, Kühl U, Cooper LT. The management of myocarditis. *Eur Heart J.* 2011;32(21):2616-25.
4. Maisch B, Alter P. Treatment options in myocarditis and inflammatory cardiomyopathy: Focus on i.v. immunoglobulins. *Herz.* 2018;43(5):423-30.
5. Kloos W, Katus HA, Meder B. Genetic cardiomyopathies. Lessons learned from humans, mice, and zebrafish. *Herz.* 2012;37(6):612-7.
6. Elliott P, Andersson B, Arbustini E, Bilinska Z, Cecchi F, Charron P, et al. Classification of the cardiomyopathies: a position statement from the European Society Of Cardiology Working Group on Myocardial and Pericardial Diseases. *Eur Heart J.* 2008;29(2):270-6.
7. Yu D-Q, Wang Y, Ma G-Z, Xu R-H, Cai Z-X, Ni C-M, et al. Intravenous immunoglobulin in the therapy of adult acute fulminant myocarditis: A retrospective study. *Exp Ther Med.* 2014;7(1):97-102.
8. Sen-Chowdhry S, Syrris P, Prasad SK, Hughes SE, Merrifield R, et al. Left-dominant arrhythmogenic cardiomyopathy: an under-recognized clinical entity. *J Am Coll Cardiol.* 2008;52(25):2175-87.
9. Burke MA, Cook SA, Seidman JG, Seidman CE. Clinical and Mechanistic Insights Into the Genetics of Cardiomyopathy. *J Am Coll Cardiol.* 2016;68(25):2871-86.
10. Gavazzi A, De Maria R, Renosto G, Moro A, Borgia M, Caroli A, et al. The spectrum of left ventricular size in dilated cardiomyopathy: clinical correlates and prognostic implications. SPIC (Italian Multicenter Cardiomyopathy Study) Group. *Am Heart J.* 1993;125(2 Pt 1):410-22.
11. Mendes LA, Picard MH, Deo GW, Hartz VL, Palacios IF, Davidoff R. Ventricular remodeling in active myocarditis. *Myocarditis Treatment Trial.* *Am Heart J.* 1999;138(2 Pt 1):303-8.
12. Emanuelsson H, Karlson BW, Herlitz J. Characteristics and prognosis of patients with acute myocardial infarction in relation to occurrence of congestive heart failure. *Eur Heart J.* 1994;15(6):761-8.
13. Yusuf S, Pearson M, Sterry H, Parish S, Ramsdale D, Rossi P, et al. The entry ECG in the early diagnosis and prognostic stratification of patients with suspected acute myocardial infarction. *Eur Heart J.* 1984;5(9):690-6.
14. Zarifa A, Kim PY, Gilchrist S, Iliescu C, Suarez-Almazor ME, Lopez-Mattei J, et al. Expression of T-cell populations and molecular markers of human myocardium with checkpoint-induced myocarditis. *J Clin Oncol.* 2019;37(8\_suppl):79-.
15. Escher F, Tschoepe C, Lassner D, Schultheiss HP. Myocarditis and inflammatory cardiomyopathy: from diagnosis to treatment. *Turk Kardiyol Dern Ars : Turk Kardiyoloji Derneginin yayin organidir.* 2015;43(8):739-48.
16. Gil KE, Pawlak A, Gil RJ, Frontczak-Baniewicz M, Bil J. The role of invasive diagnostics and its impact on the treatment of dilated cardiomyopathy: A systematic review. *Adv Med Sci.* 2016;61(2):331-43.
17. Di Filippo S. Improving outcomes of acute myocarditis in children. *Expert Rev Cardiovasc Ther.* 2016;14(1):117-25.
18. Ando T, Yamasaki Y, Takakuwa Y, Iida H, Asari Y, Suzuki K, et al. Concurrent onset of acute lupus myocarditis, pulmonary arterial hypertension and digital gangrene in a lupus patient: a possible role of vasculitis to the rare disorders. *Modern Rheumatology Case Reports.* 2019(just-accepted):1-14.
19. Johnson N, Suri D, Gupta A, Rawat A, Singh S. 137 Myocarditis in pediatric lupus: A clinical conundrum. *Arch Dis Child;* 2019.
20. Meier LA, Binstadt BA. The Contribution of

## Intravenous Immunoglobulin Therapy in Myocarditis

- Autoantibodies to Inflammatory Cardiovascular Pathology. *Front Immunol*. 2018;9(911).
21. Caforio AL, Mahon NJ, Tona F, McKenna WJ. Circulating cardiac autoantibodies in dilated cardiomyopathy and myocarditis: pathogenetic and clinical significance. *Eur J Heart Fail*. 2002;4(4):411-7.
  22. Neu N, Beisel K, Traystman M, Rose N, Craig S. Autoantibodies specific for the cardiac myosin isoform are found in mice susceptible to Cocksackievirus B3-induced myocarditis. *J Immunol*. 1987;138(8):2488-92.
  23. Nagatomo Y, Tang WW. Autoantibodies and cardiovascular dysfunction: cause or consequence? *Curr Heart Fail Rep*. 2014;11(4):500-8.
  24. Nussinovitch U, Shoenfeld Y. The clinical and diagnostic significance of anti-myosin autoantibodies in cardiac disease. *Clin Rev Allergy Immunol*. 2013;44(1):98-108.
  25. Nagatomo Y, Tang WHW. Autoantibodies and cardiovascular dysfunction: cause or consequence? *Curr Heart Fail Rep*. 2014;11(4):500-8.
  26. Warraich RS, Noutsias M, Kasac I, Seeberg B, Dunn MJ, Schultheiss H-P, et al. Immunoglobulin G3 cardiac myosin autoantibodies correlate with left ventricular dysfunction in patients with dilated cardiomyopathy: immunoglobulin G3 and clinical correlates. *Am Heart J*. 2002;143(6):1076-84.
  27. Caforio AL, Tona F, Bottaro S, Vinci A, Dequal G, Daliento L, et al. Clinical implications of anti-heart autoantibodies in myocarditis and dilated cardiomyopathy. *Autoimmunity*. 2008;41(1):35-45.
  28. Vilela EM, Bettencourt-Silva R, da Costa JT, Barbosa AR, Silva MP, Teixeira M, et al. Anti-cardiac troponin antibodies in clinical human disease: a systematic review. *Ann Transl Med*. 2017;5(15):307-.
  29. Shabaniyan R, Abozari M, Kiani A, Seifirad S, Zamani G, Nahalimoghaddam A, Kochanian A. Myocardial performance index and atrial ejection force in patients with Duchenne's muscular dystrophy. *Echocardiography*. 2011;28(10): 1088-1094.
  30. Pettersson K, Eriksson S, Wittfooth S, Engström E, Nieminen M, Sinisalo J. Autoantibodies to cardiac troponin associate with higher initial concentrations and longer release of troponin I in acute coronary syndrome patients. *Clin Chem*. 2009;55(5):938-45.
  31. Chen G, Chelu MG, Dobrev D, Li N. Cardiomyocyte Inflammasome Signaling in Cardiomyopathies and Atrial Fibrillation: Mechanisms and Potential Therapeutic Implications. *Front Physiol*. 2018;9:1115-.
  32. Próchnicki T, Mangan MS, Latz E. Recent insights into the molecular mechanisms of the NLRP3 inflammasome activation. *F1000Res*. 2016;5:F1000 Faculty Rev-469.
  33. Guo H, Callaway JB, Ting JPY. Inflammasomes: mechanism of action, role in disease, and therapeutics. *Nat Med*. 2015;21(7):677-87.
  34. Smith SC, Ladenson JH, Mason JW, Jaffe AS. Elevations of cardiac troponin I associated with myocarditis. Experimental and clinical correlates. *Circulation*. 1997;95(1):163-8.
  35. Gelfand EW. Intravenous Immune Globulin in Autoimmune and Inflammatory Diseases. *N Engl J Med*. 2012;367(21):2015-25.
  36. Prasad AN, Chaudhary S. Intravenous immunoglobulin in pediatrics: A review. *Med J Armed Forces India*. 2014;70(3):277-80.
  37. Schwab I, Nimmerjahn F. Intravenous immunoglobulin therapy: how does IgG modulate the immune system? *Nat Rev Immunol*. 2013;13:176.
  38. Miyata K, Kaneko T, Morikawa Y, Sakakibara H, Matsushima T, Misawa M, et al. Efficacy and safety of intravenous immunoglobulin plus prednisolone therapy in patients with Kawasaki disease (Post RAISE): a multicentre, prospective cohort study. *Lancet Child Adolesc Health*. 2018;2(12):855-62.
  39. Kim HS, Sohn S, Park JY, Seo JW. Fulminant myocarditis successfully treated with high-dose immunoglobulin. *Int J Cardiol*. 2004;96(3):485-6.
  40. Haque A, Bhatti S, Siddiqui FJ. Intravenous immune globulin for severe acute myocarditis in children. *Indian Pediatr*. 2009;46(9).
  41. Stouffer GA, Sheahan RG, Lenihan DJ, Patel P. The current status of immune modulating therapy for myocarditis: a case of acute parvovirus myocarditis treated with intravenous immunoglobulin. *Am J Med Sci*. 2003;326(6):369-74.
  42. Drucker NA, Colan SD, Lewis AB, Beiser AS, Wessel DL, Takahashi M, et al. Gamma-globulin treatment of acute myocarditis in the pediatric population. *Circulation*. 1994;89(1):252-7.
  43. Schroeder HW, Jr., Dougherty CJ. Review of intravenous immunoglobulin replacement therapy trials for primary humoral immunodeficiency patients. *Infection*. 2012;40(6):601-11.
  44. Sewell WAC, Jolles S. Immunomodulatory action of intravenous immunoglobulin. *Immunology*. 2002;107(4):387-93.
  45. Hartung HP, Mouthon L, Ahmed R, Jordan S, Laupland K, Jolles S. Clinical applications of intravenous immunoglobulins (IVIg)—beyond immunodeficiencies and neurology. *Clin Exp Immunol*. 2009;158:23-33.
  46. Stangel M, Pul R. Basic principles of intravenous immunoglobulin (IVIg) treatment. *J Neurol*.

- 2006;253(5):v18-v24.
47. Steele R, Burks JA, Williams L. Intravenous immunoglobulin: new clinical applications. *Ann Allergy.* 1988;60(2):89-94.
  48. Ballou M. Mechanisms of immune regulation by IVIG. *Curr Opin Allergy Clin Immunol.* 2014;14(6):509-15.
  49. Bayry J, Misra N, Latry V, Prost F, et al. Mechanisms of action of intravenous immunoglobulin in autoimmune and inflammatory diseases. *Transfusion clinique et biologique : journal de la Societe francaise de transfusion sanguine.* 2003;10(3):165-9.
  50. Tha-In T, Bayry J, Metselaar HJ, Kaveri SV, Kwekkeboom J. Modulation of the cellular immune system by intravenous immunoglobulin. *Trends Immunol.* 2008;29(12):608-15.
  51. Samuelsson A, Towers TL, Ravetch JV. Anti-inflammatory activity of IVIG mediated through the inhibitory Fc receptor. *Science.* 2001;291(5503):484-6.
  52. Hartung HP. Advances in the understanding of the mechanism of action of IVIg. *J Neurol.* 2008;255 Suppl 3:3-6.
  53. Crow AR, Brinc D, Lazarus AH. New insight into the mechanism of action of IVIg: the role of dendritic cells. *J Thromb Haemost.* 2009;7 Suppl 1:245-8.
  54. Basta M, Kirshbom P, Frank MM, Fries LF. Mechanism of therapeutic effect of high-dose intravenous immunoglobulin. Attenuation of acute, complement-dependent immune damage in a guinea pig model. *J Clin Invest.* 1989;84(6):1974-81.
  55. Jolles S, Sewell WAC, Misbah SA. Clinical uses of intravenous immunoglobulin. *Clin Exp Immunol.* 2005;142(1):1-11.
  56. Huang X, Sun Y, Su G, Li Y, Shuai X. Intravenous Immunoglobulin Therapy for Acute Myocarditis in Children and Adults. *Int Heart J.* 2019;60(2):359-65.
  57. Udi N, Yehuda S. Intravenous immunoglobulin—indications and mechanisms in cardiovascular diseases. *Autoimmun Rev.* 2008;7(6):445-52.
  58. Klassen T, Hartling L, Vandermeer B, Robinson J. Intravenous immunoglobulin for presumed viral myocarditis in children and adults. 2005.
  59. Dorner A, Grunert HP, Lindig V, Chandrasekharan K, Fechner H, Knowlton KU, et al. Treatment of coxsackievirus-B3-infected BALB/c mice with the soluble coxsackie adenovirus receptor CAR4/7 aggravates cardiac injury. *J Mol Med (Berlin, Germany).* 2006;84(10):842-51.
  60. Drucker NA, Colan SD, Lewis AB, Beiser AS, Wessel DL, Takahashi M, et al. Gamma-globulin treatment of acute myocarditis in the pediatric population. *Circulation.* 1994;89(1):252-7.
  61. Störk S, Boivin V, Horf R, Hein L, Lohse MJ, Angermann CE, et al. Stimulating autoantibodies directed against the cardiac  $\beta$ 1-adrenergic receptor predict increased mortality in idiopathic cardiomyopathy. *Am Heart J.* 2006;152(4):697-704.
  62. Agarwal S, Agrawal DK. Kawasaki disease: etiopathogenesis and novel treatment strategies. *Expert Rev Clin Immunol.* 2017;13(3):247-58.
  63. Han JW. The Efficacy and Safety of High-Dose Intravenous Immunoglobulin in the Treatment of Kawasaki Disease: How Can We Predict Resistance to Intravenous Immunoglobulin Treatment of Kawasaki Disease? *Korean Circ J.* 2017;47(2):179-81.
  64. Furusho K, Nakano H, Shinomiya K, Yamura T, Manabe Y, Kawarano M, et al. High-dose intravenous gammaglobulin for Kawasaki disease. *Lancet.* 1984;324(8411):1055-8.
  65. Sundel RP. Kawasaki disease. *Rheum Dis Clin North Am.* 2015;41(1):63-73, viii.
  66. Newburger JW, Takahashi M, Beiser AS, Burns JC, Bastian J, Chung KJ, et al. A single intravenous infusion of gamma globulin as compared with four infusions in the treatment of acute Kawasaki syndrome. *N Engl J Med.* 1991;324(23):1633-9.
  67. Newburger JW, Takahashi M, Burns JC, Beiser AS, Chung KJ, Duffy CE, et al. The treatment of Kawasaki syndrome with intravenous gamma globulin. *N Engl J Med.* 1986;315(6):341-7.
  68. Oates-Whitehead RM, Baumer JH, Haines L, Love S, Maconochie IK, Gupta A, et al. Intravenous immunoglobulin for the treatment of Kawasaki disease in children. *Cochrane Database Syst Rev.* 2003(4).
  69. Veronese G, Ammirati E, Cipriani M, Frigerio M. Fulminant myocarditis: Characteristics, treatment, and outcomes. *Anatol J Cardiol.* 2018;19(4):279-86.
  70. Yu DQ, Wang Y, Ma GZ, Xu RH, Cai ZX, Ni CM, et al. Intravenous immunoglobulin in the therapy of adult acute fulminant myocarditis: A retrospective study. *Exp Ther Med.* 2014;7(1):97-102.
  71. Yoshimatsu Y, Kotani T, Fujiki Y, Oda K, Kataoka T, et al. Successful treatment with intravenous high-dose immunoglobulin for cardiomyopathy in dermatomyositis complicated with rapid progressive interstitial pneumonia. *Int J Rheum Dis.* 2019;22(2):321-4.
  72. Huang X, Sun Y, Su G, Li Y, Shuai X. Intravenous Immunoglobulin Therapy for Acute Myocarditis in Children and Adults. *Int Heart J.* 2019;60(2):359-65.
  73. Kishimoto C, Shioji K, Kinoshita M, Iwase T, Tamaki S,

## Intravenous Immunoglobulin Therapy in Myocarditis

- Fujii M, et al. Treatment of acute inflammatory cardiomyopathy with intravenous immunoglobulin ameliorates left ventricular function associated with suppression of inflammatory cytokines and decreased oxidative stress. *Int J Cardiol.* 2003;91(2-3):173-8.
74. Cardiomyopathy. *Am Fam Physician.* 2017;96(10):Online.
75. Goland S, Czer LS, Siegel RJ, Tabak S, Jordan S, Luthringer D, et al. Intravenous immunoglobulin treatment for acute fulminant inflammatory cardiomyopathy: series of six patients and review of literature. *Can J Cardiol.* 2008;24(7):571-4.
76. Xu J, Brooks EG. Giant Cell Myocarditis: A Brief Review. *Arch Pathol Lab Med.* 2016;140(12):1429-34.
77. Laufs H, Nigrovic PA, Schneider LC, Oettgen H, del Nido P, Moskowitz IP, et al., editors. Giant cell myocarditis in a 12-year-old girl with common variable immunodeficiency. *Mayo Clin Proc.* 2002: Elsevier.
78. Hurst JW, Morris DC, Alexander RW. The use of the New York Heart Association's classification of cardiovascular disease as part of the patient's complete Problem List. *Clin Cardiol.* 1999;22(6):385-90.
79. Bozkurt B, Villaneuva FS, Holubkov R, Tokarczyk T, Alvarez RJ, Jr., et al. Intravenous immune globulin in the therapy of peripartum cardiomyopathy. *J Am Coll Cardiol.* 1999;34(1):177-80.
80. Felix SB, Staudt A, Dorffle WV, Stangl V, Merkel K, Pohl M, et al. Hemodynamic effects of immunoadsorption and subsequent immunoglobulin substitution in dilated cardiomyopathy: three-month results from a randomized study. *J Am Coll Cardiol.* 2000;35(6):1590-8.
81. McNamara DM, Holubkov R, Starling RC, Dec GW, Loh E, Torre-Amione G, et al. Controlled trial of intravenous immune globulin in recent-onset dilated cardiomyopathy. *Circulation.* 2001;103(18):2254-9.
82. Lin MS, Tseng YH, Chen MY, Chung CM, Tsai MH, Wang PC, et al. In-hospital and post-discharge outcomes of pediatric acute myocarditis underwent after high-dose steroid or intravenous immunoglobulin therapy. *BMC Cardiovasc Disord.* 2019;19(1):10.
83. Guo Y, Tian X, Wang X, Xiao Z. Adverse Effects of Immunoglobulin Therapy. *Front Immunol.* 2018;9:1299-.
84. Katz U, Achiron A, Sherer Y, Shoenfeld Y. Safety of intravenous immunoglobulin (IVIg) therapy. *Autoimmun Rev.* 2007;6(4):257-9.
85. Calonge M, Perez I, Galindo S, Nieto-Miguel T, Lopez-Paniagua M, et al. A proof-of-concept clinical trial using mesenchymal stem cells for the treatment of corneal epithelial stem cell deficiency. *Translational research : J Lab Clin Med.* 2019;206:18-40.
86. Shojaei F, Rahmati S, Banitalebi Dehkordi M. A review on different methods to increase the efficiency of mesenchymal stem cell-based wound therapy. *Wound Repair Regen: official publication of the Wound Healing Society [and] the European Tissue Repair Society.* 2019.
87. Berg J, Lovrinovic M, Baltensperger N, Kissel CK, Kottwitz J, Manka R, et al. Non-steroidal anti-inflammatory drug use in acute myopericarditis: 12-month clinical follow-up. *Open Heart.* 2019;6(1):e000990.
88. Winter MP, Sulzgruber P, Koller L, Bartko P, Goliash G, Niessner A. Immunomodulatory treatment for lymphocytic myocarditis-a systematic review and meta-analysis. *Heart Fail Rev.* 2018;23(4):573-81.
89. Mou SS, McCrory MC. 28 - Inflammatory Heart Disease: Pericardial Effusion and Tamponade, Pericarditis, and Myocarditis. In: Ungerleider RM, Meliones JN, Nelson McMillan K, Cooper DS, Jacobs JP, editors. *Critical Heart Disease in Infants and Children (Third Edition).* Philadelphia: Elsevier; 2019. p. 351-64.e5.
90. Vetter VL, Covington TM, Dugan NP, Haley DM, et al. Cardiovascular deaths in children: General overview from the National Center for the Review and Prevention of Child Deaths. *Am Heart J.* 2015;169(3):426-37.e23.
91. Milani P, Dispenzieri A, Scott CG, Gertz MA, Perlini S, Mussinelli R, et al. Independent Prognostic Value of Stroke Volume Index in Patients With Immunoglobulin Light Chain Amyloidosis. *Circ Cardiovasc Imaging.* 2018;11(5):e006588.
92. Riehle C, Bauersachs J. Key inflammatory mechanisms underlying heart failure. *Herz.* 2019;44(2):96-106.
93. Ius F, Sommer W, Verboom M, Salman J, Siemieni T, Kühn C, et al. Five-Year Results of an IgA-and IgM-Enriched Human Immunoglobulin-Based Therapy for Early anti-HLA Donor-Specific Antibodies after Lung Transplantation. *Thorac Cardiovasc Surg.* 2019;67(S 01):DGTHG-V222.
94. Anthony RM, Nimmerjahn F, Ashline DJ, Reinhold VN, Paulson JC, Ravetch JV. Recapitulation of IVIg anti-inflammatory activity with a recombinant IgG Fc. *Science.* 2008;320(5874):373-6.
95. Shah Z, Vuddanda VV, Bischoff MM, et al. Utilization and Impact of Right Heart Catheterization on In-hospital Mortality, Length of hospital Stay and 30 Day Readmission in Patients Admitted with Cardiogenic Shock - Review of Large, National, Multicenter Database. *J Card Fail.* 2018;24(8):S96.
96. Li S, Xu S, Li C, Ran X, Cui G, He M, et al. A life support-based comprehensive treatment regimen

- dramatically lowers the in-hospital mortality of patients with fulminant myocarditis: a multiple center study. *Sci China Life Sci.* 2019;62(3):369-80.
97. Yen CY, Hung MC, Wong YC, Chang CY, Lai CC, Wu KG. Role of intravenous immunoglobulin therapy in the survival rate of pediatric patients with acute myocarditis: A systematic review and meta-analysis. *Sci Rep.* 2019;9(1):10459.
98. McNamara DM, Rosenblum WD, Janosko KM, Trost MK, Villaneuva FS, Demetris A, et al. Intravenous immune globulin in the therapy of myocarditis and acute cardiomyopathy. *Circulation.* 1997;95(11):2476-8.
99. Kishimoto C, Fujita M, Kinoshita M, Iwase T, Fujii B, Murashige A, et al., editors. Immunoglobulin therapy for myocarditis and acute dilated cardiomyopathy. *Circulation*; 1999: LIPPINCOTT WILLIAMS & WILKINS 530 WALNUT ST, PHILADELPHIA, PA 19106-3621 USA.
100. Maisch B, Haake H, Schlotmann N, Pankuweit S. Intermediate dose of pentaglobin eradicates effectively inflammation in parvo B19 and adenovirus positive myocarditis. *Am Heart Assoc*; 2007.
101. Tedeschi A, Airaghi L, Giannini S, Cicetti L, Massari F. High-dose intravenous immunoglobulin in the treatment of acute myocarditis. A case report and review of the literature. *J Intern Med.* 2002;251(2):169-73.
102. Atiq M, Hoda M, Aslam N. Effect of intravenous gamma globulin on short-and mid-term clinical outcome in acute viral myocarditis in children. *World J Cardiovasc Dis.* 2014;2014.
103. El-Saiedi SA. Randomized controlled trial on the use of intravenous immune globulin in acute pediatric myocarditis. *J Clin Res Biotech.* 2013;5:170.