

# High Doses Intravenous Immunoglobulin versus Oral Cyclosporine in the Treatment of Severe Atopic Dermatitis

Mohammad Hassan Bemanian, Masoud Movahedi, Abolhassan Farhoudi,  
Mohammad Gharagozlou, Mehran Heidari Seraj, Zahra Pourpak, Mohammad Nabavi,  
Asghar Aghamohammadi, and Zahra Shirkhoda

*Department of Immunology, Asthma and Allergy, Children's Hospital Medical Center,  
Tehran University of Medical Sciences, Tehran, Iran*

## ABSTRACT

Atopic dermatitis is one of the most common allergic diseases that almost always respond to conventional therapies with topical emollient, topical corticosteroids, systemic antihistamines and allergic abstinence. However few cases of atopic dermatitis with severe course do not respond to conventional therapies and high dose of intravenous immunoglobulin or cyclosporine are recommended for them. This clinical trial study has been done to compare the last two regimens in patients with severe atopic dermatitis, Scoring Atopic Dermatitis (SCORAD) > 70. We included 14 patients in two groups. In group 1, eight patients were randomly selected and received 4mg/kg cyclosporine daily for 3 months and in group 2, six patients received 2g/kg Intravenous Immunoglobulin (IVIG) as stat infusion. All patients were followed on days 15, 30, 60 and 90 after starting the therapy. About 75% and 62.5% of patients had positive skin tests to egg and to milk respectively. Six patients out of 14 patients did not have skin test, so specific IgE by Radioallergosorbent tests (RAST) was used for them. All of these patients had positive RAST to egg and 66.6% against cow's milk.

There was a significant difference in the clinical outcomes of these two groups with a marked reduction in SCORAD of day 90<sup>th</sup> in group 1 in comparison to group 2 (P-value = 0.005). No significant adverse drug reaction was seen in these two groups.

**Keywords:** Atopic dermatitis; Cyclosporine; Intravenous immunoglobulin; Treatment

## INTRODUCTION

Atopic dermatitis, one of the most common skin disorders seen in infants and children, usually has its onset during the first 6 months of life.<sup>1</sup> Treatment of atopic dermatitis requires a comprehensive approach that includes evaluation of potential triggers and education of the patient and family regarding the proper avoidance measures. Hydration of skin barrier remains integral to proper management.<sup>2</sup>

Although topical corticosteroids have been a mainstay of anti-inflammatory therapy but alternative treatment modalities may be especially useful for patients in whom corticosteroid resistance contributing to treatment failure, so therapy directed for correcting the immune dysfunction is suggested. Cyclosporine A is an effective and well-tolerated treatment for severe atopic dermatitis. In an open prospective study, ten children with severe atopic dermatitis who were treated with cyclosporine A, demonstrated significant improvement but data for uses of cyclosporine A in children are limited.<sup>4</sup> Intravenous immunoglobulin treatment has been shown to be beneficial in a few open studies but evidence of effectiveness is still lacking.<sup>5</sup>

---

**Corresponding Author:** Mohammad Hassan Bemanian, MD;  
Department of Immunology, Asthma and Allergy, Children's  
Hospital Medical Center, Tehran University of Medical Sciences  
Tehran, Iran. Tel: (+98 913) 351 8760, Fax: (+98 216) 6428 995,  
E-mail: mhbemanian@razi.tums.ac.ir

## Treatment of Severe Atopic Dermatitis

Therefore the aim of this study was to investigate whether treatment with cyclosporine A is safe and effective and also to evaluate the efficacy of treatment with intravenous Immunoglobulin in severe atopic dermatitis and cost effectiveness of these two modalities compared with each other. A search of the literature revealed no published studies comparing these two modalities in the treatment of severe atopic dermatitis.

### MATERIALS AND METHODS

In this clinical trial study 16 patients with atopic dermatitis by Hanifin and Rajka modified diagnostic criteria were included.<sup>6</sup>

Two patients excluded, due to poor cooperation. The patients were referred to Immunology and Allergy clinic of the Children's Hospital Medical center from September 2003 to January 2005.

All patients with severe atopic dermatitis (SCORAD > 70) who failed to respond to the first and second line of therapy<sup>7</sup> were enrolled in this study. The patients were thoroughly informed about the study and for each patient two standard questionnaires were completed. In the first demographic data and clinical information, laboratory data such as total IgE (ELISA kit for detection of total IgE), eosinophil count, specific IgE against common food allergens including cows milk, egg, wheat, soya, peanut, fish and common aeroallergen including trees, weeds, grasses, mites were included (Allergopharma, Germany). In the second questionnaire form severity of atopic dermatitis with SCORAD was recorded at the days of 0, 15<sup>th</sup>, 30<sup>th</sup>, 60<sup>th</sup> and 90<sup>th</sup> of therapy. We randomized the participants into one of the two treatment groups, group 1 with oral cyclosporine 4mg/kg (Neoral-Novartis) daily for 3 months and group 2 with single dose of 2gr/kg intravenous immunoglobulin (Sandglobulin-Novartis), as slow IV infusion through 4-8 hours (1 drop/kg/min) after hospital admission. Then all the patients were evaluated for probable adverse drug reactions and clinical improvement in follow up examinations on days 15, 30, 60 and 90 after treatment.

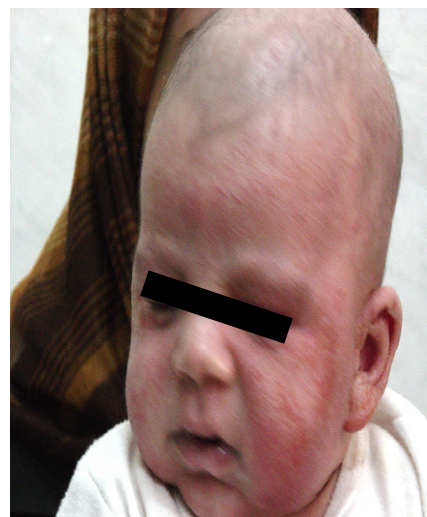All patients used daily emollient, post bathing for skin hydration and oral Hydroxysin (0.5mg/kg at bed time) and topical corticosteroid in short courses when there was flaring up of the dermatitis, systemic antibiotic (Cephalexin) or topical antibiotics

(Mupirocin) were prescribed if there was clinical evidence of bacterial super imposed infection.

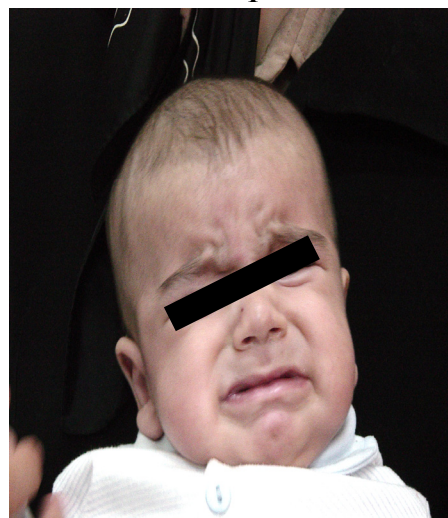### RESULTS

Fourteen patients with severe atopic dermatitis were enrolled into two groups: in group 1, eight patients (4 male and 4 female) with median age of  $11.91 \pm 4.29$  years old and in group 2, six patients (3 male, 3 female) with median age of  $6.44 \pm 1.59$  (P-value = 0.31).

Median eosinophil count in group 1 was 646.25 cells/mm<sup>3</sup> and in group 2 was 2109.5 cells/mm<sup>3</sup> (P-value = 0.47).

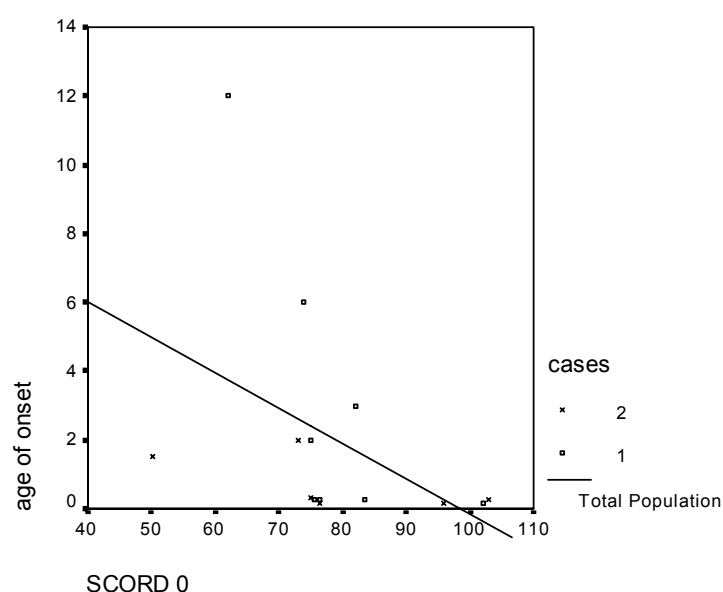


1



2

**Figure 1. Severe atopic dermatitis with erythrodermic distribution of skin before (1) and after (2) treatment with cyclosporine.**



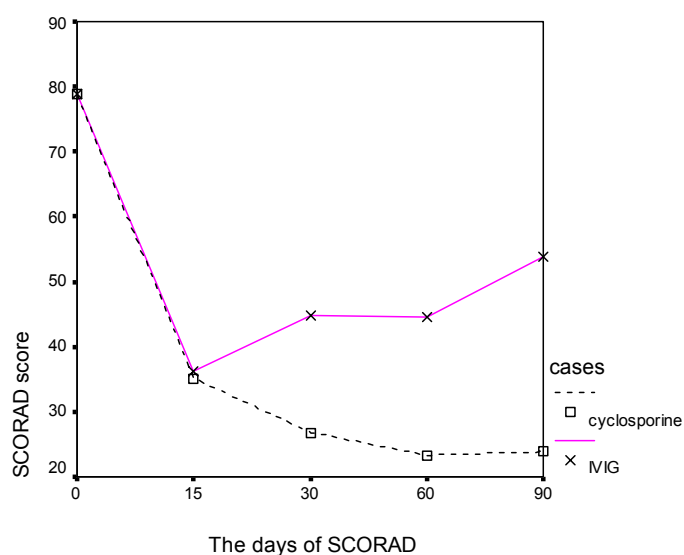
**Figure 2. Relationship between age of onset in atopic dermatitis and severity of disease.**

Median of total IgE serum level in group 1 was 947.38mg/dl and 1441.67mg/dl in group 2 (P-value = 0.155). Positive skin prick test to whole egg was seen in 75% of all patients and about 25% had positive skin test to trees and mites.

Six patients could not have skin prick test due to diffuse cutaneous involvement or inability to stop antihistamines, so RAST for detecting specific IgE to allergen was done. All of them (100%) showed positive RAST against egg, 66.6% against cow's milk and 66.6% against mites but only 16.6% against

weeds. Reduction in SCORAD was seen in both groups on 15<sup>th</sup> day but it had continuous deceleration in group 1 but was not observed in group 2 (Figure 1). There was negative correlation between age of onset in atopic dermatitis and severity of disease, the younger the patients at presentation the more severe dermatitis (Figure 2).

There was not any permanent organ damage due to side effects of IVIG or cyclosporine, and all side effects were transient, which disappeared with discontinuing medication (Table 1).



**Figure 3. Comparison of SCORAD trends in patients were treated with cyclosporine (----) and IVIG (—).**

## Treatment of Severe Atopic Dermatitis

**Table 1. Adverse drug reaction in two groups.**

Complication / Cases	Fever and chills	Hirsutism	Herpetic kerato- conjunctivitis
Group 1(n=8)	0/8	1/8	1/8
Group 2(n=6)	2/6	0/6	0/6
Percent	33.33	12.5	12.5

In this study, non parametric method was used for statistical analysis due to little number of patients, Mann- Whitney test was used for comparing SCORAD of two groups.

### DISCUSSION

A broad set of systemic immunomodulatory agents have been used for severe atopic dermatitis refractory to topical therapies<sup>8</sup> but which of them is more effective and with the least side effect and which of them is cost effective?

In our study two groups were matched according to sex, age, and severity of disease. Food allergies have a pathogenetic role in a subset of patients with atopic dermatitis, particularly in infants.<sup>9</sup> In our study due to limited number of patients, prevalence rate could not be estimated but similar to other studies egg and cow's milk were at the top of the list of allergen culprits in exacerbation of atopic dermatitis (75% positive skin test to egg and 62.5% positive skin test to cow's milk) similar result was also seen with RAST test.

Exposure to mite and some other aeroallergens can induce flare up of atopic dermatitis.<sup>10</sup> In this study 37.5% of patients had positive skin test to pollen trees and 25% to mite and also 66.6% of patients had positive RAST to mite and 16.6% positive RAST to weeds.

This study provides evidence that cyclosporine is safe and effective in children as adult with atopic dermatitis, as it has been demonstrated in multiple studies<sup>11,12</sup> however clinical efficacy of high dose IVIG which is transient and its cost – effectiveness must be evaluated regarding to expensiveness of this drug.

An open label study was done by Stiehm et al, 1998 to determine high dose IVIG whether it would be beneficial for patients with severe atopic dermatitis, nine patients, out of ten, had severe atopic

dermatitis and one with hyper IgE syndrome. All patients received 2gr/kg IVIG every 30 days for seven infusions. They concluded that IVIG had no clear clinical benefit.<sup>13</sup> In another study, six patients with severe atopic dermatitis received 2g/kg IVIG in 6 cycles (every month) and in 3 months follow up, four patients had major improvement in SCORAD.<sup>14</sup> IVIG treatment could improve clinical signs and symptoms but it is very expensive and needed frequent periodic administration. In comparison, cyclosporine is relatively cheap, available, safe and more effective in improving clinical signs and symptoms of severe atopic dermatitis which are refractory to treatment (Figure 3).

### REFERENCES

1. Kay J, Gawkrödger DJ, Mortimer MJ, Jaron AG. The prevalence of childhood atopic eczema in a general population. *J Am Acad Dermatol* 1994; 30(1):35-9.
2. Boguniewicz M, Eichenfield LF, Hultsch T. Current management of atopic dermatitis and interruption of the atopic march. *J Allergy Clin Immunol* 2003; 112(6 Suppl):140-50.
3. Bunikowski R, Staab D, Kussebi F, Brautigam M, Weidinger G, Renz H, et al. Low-dose cyclosporin A microemulsion in children with severe atopic dermatitis: clinical and immunological effects. *Pediatr Allergy Immunol* 2001; 12(4):216-23.
4. Boguniewicz M, Leung DYM: Atopic dermatitis. In: Middleton's Allergy principles and practice. USA: Mosby, Elsevier, 2003: 1559-75.
5. Paul C, Lahfa M, Bachelez H, Chevret S, Dubertret L. A randomized controlled evaluator-blinded trial of intravenous immunoglobulin in adults with severe atopic dermatitis. *Br J Dermatol* 2002; 147(3):518-22.
6. Williams HC, Burney PG, Hay RJ, Archer CB, Shipley MJ, Hunter JJ, et al. The U.K. Working Party's Diagnostic Criteria for Atopic Dermatitis. I. Derivation of a minimum set of discriminators for atopic dermatitis. *Br J Dermatol* 1994; 131(3):383-96.
7. E. Ann Bingham, Guidelines to management of atopic dermatitis John Harper, Arnold orange, and Neil prose In: Text book of pediatric dermatolog. U.K Blackwell Science 2000: 215–30.
8. Sidbury R, Hanifin JM. Systemic therapy of atopic dermatitis. *Clin Exp Dermatol* 2000; 25(7):239-66.

9. Novak N, Bieber T, Leung DY. Immune mechanisms leading to atopic dermatitis. *J Allergy Clin Immunol* 2003; 112(6 Suppl):128-39.
10. Tan BB, Weald D, Strickland I, Friedmann PS. Double-blind controlled trial of effect of housedust-mite allergen avoidance on atopic dermatitis. *Lancet* 1996; 347(8993):15-8.
11. Berth-Jones J, Finlay AY, Zaki I, Tan B, Goodyear H, Lewis-Jones S, et al. Cyclosporine in severe childhood atopic dermatitis: a multicenter study. *J Am Acad Dermatol* 1996; 34(6):1016-21.
12. Zonneveld IM, De Rie MA, Beljaards RC, Van Der Rhee HJ, Wuite J, Zeegelaar J, et al. The long-term safety and efficacy of cyclosporin in severe refractory atopic dermatitis: a comparison of two dosage regimens. *Br J Dermatol* 1996; 135(Suppl 48):15-20.
13. Wakim M, Alazard M, Yajima A, Speights D, Saxon A, Stiehm ER. High dose intravenous immunoglobulin in atopic dermatitis and hyper-IgE syndrome. *Ann Allergy Asthma Immunol* 1998; 81(2):153-8.
14. Jolles S, Sewell C, Webster D, Ryan A, Heelan B, Waite A, et al. Adjunctive high-dose intravenous immunoglobulin treatment for resistant atopic dermatitis: efficacy and effects on intracellular cytokine levels and CD4 counts. *Acta Derm Venereol* 2003; 83(6):433-7.

## Editorial Comment

Although the results of clinical trial reported by Dr. M.H. Bemanian and his colleagues is in favor of a specific medicine, editorial board of the Iranian Journal of Allergy, Asthma and Immunology avoid any unconditional confirmation of a pharmaceutical product and we leave the choice to the physicians to choose, considering all aspects of the issue in particular the results of other related studies.